

6-1-2010

## What is Your Diagnosis?

Pranee Tuntivanich

Suwicha Chuthateph

Follow this and additional works at: <https://digital.car.chula.ac.th/tjvm>



Part of the [Veterinary Medicine Commons](#)

---

### Recommended Citation

Tuntivanich, Pranee and Chuthateph, Suwicha (2010) "What is Your Diagnosis?," *The Thai Journal of Veterinary Medicine*: Vol. 40: Iss. 2, Article 16.

Available at: <https://digital.car.chula.ac.th/tjvm/vol40/iss2/16>

This Other is brought to you for free and open access by the Chulalongkorn Journal Online (CUJO) at Chula Digital Collections. It has been accepted for inclusion in The Thai Journal of Veterinary Medicine by an authorized editor of Chula Digital Collections. For more information, please contact [ChulaDC@car.chula.ac.th](mailto:ChulaDC@car.chula.ac.th).

## WHAT IS YOUR DIAGNOSIS

Pranee Tuntivanich\* Suwicha Chuthateph

### *Signalment*

A 1-year-old male Persian cat.

### *History*

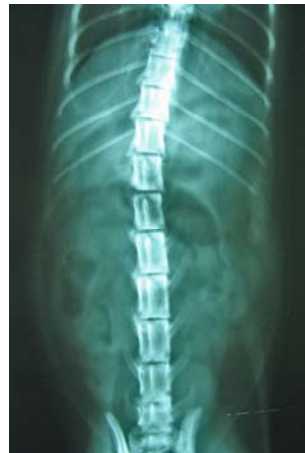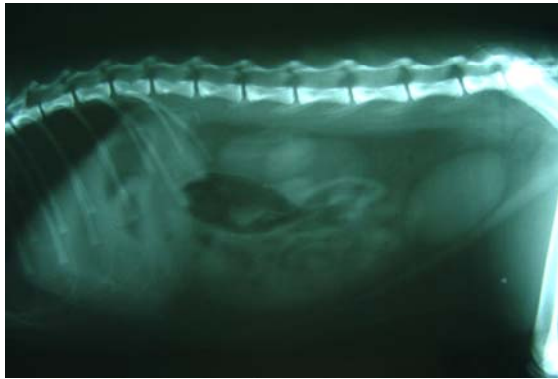
This cat had presented a severe vomiting (5 times) during the past 8 hours. The cat refused to have a food. The owner notices that he loves playing fabric ropes.

### *Clinical Examination*

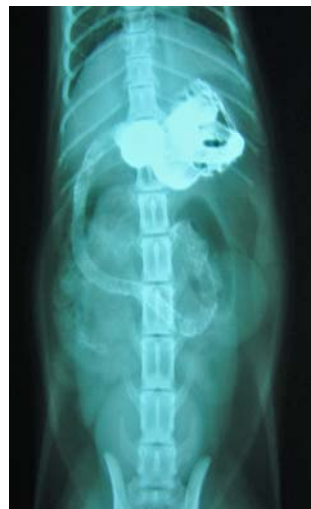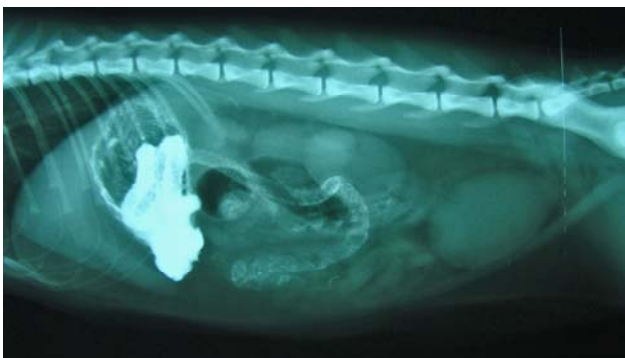Mucous membrane was normally pink. Even though there was no abdominal distension, the cat was uncomfortable during abdominal palpation. Low-graded fever was detected.

### *Radiographic Examination*

Right lateral and ventrodorsal abdominal radiographs were taken initially, followed by regular 30 minutes interval radiographs taken after barium swallowing to investigate upper gastrointestinal (GI) abnormalities.



**Figure 1** Right lateral (A) and ventrodorsal (B) abdominal radiographs.



**Figure 2** Right lateral (A) and ventrodorsal (B) abdominal radiographs taken at 2 hours after barium sulphate suspension administration.

Give your diagnosis and turn to the next page.

### **Radiographic findings**

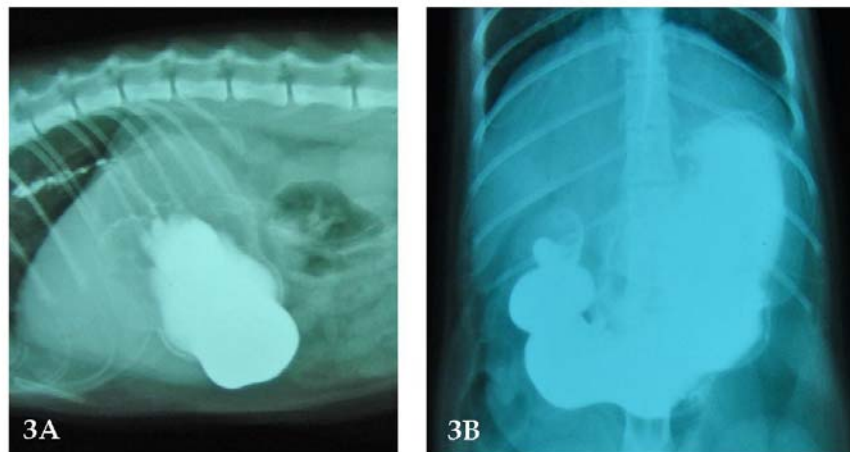
Plain abdominal radiographs (Figures 1A & 1B) revealed small amount of natural gas in the fundus and body of stomach. An intestinal obstructive sign, gas-filled bowel loops causing small intestinal distension, could not be seen. There was no appearance of upper GI organ displacement. Contrast radiographs (Figures 2A & 2B) showed a filling defect of barium sulphate surround the foreign body which was placing along the pylorus and duodenum. Delayed onset of gastric emptying was detected due to a large amount of barium sulphate remained in the stomach.

### **Radiographic diagnosis**

Linear foreign body in upper gastrointestinal tract

### **Discussion**

The most common agent used for contrast radiography of the upper GI tract is barium sulphate suspension. Location of filled contrast in the stomach will be different depending on the radiographic positioning; in pylorus (right lateral view), in the fundus (left lateral view), in fundus and pylorus (ventrodorsal view) or in stomach body (dorsoventral view). Hence, several radiographic views are deeply suggested in order to indicate location of the lesions. However, the volume of the contrast, the previous drug administration or sufficient numbers of serial radiographs should be considered since it can be an influence on radiographic interpretation. To interpret GI contrast radiographs, the onset/rate of gastric emptying, small intestinal transit time, position of the stomach and small intestine, GI wall thickening, filling defect and contrast leakage should be assessed. As an alternative in cases that have severe regurgitation or severe vomiting, water soluble iodine contrast could be used in instead of barium to decrease a chance of barium aspiration.



**Figure 3** Right lateral (A) and ventrodorsal (B) abdominal radiographs taken at time 30 minutes after barium swallow showed an obliterated foreign body in contrast puddle. Therefore serial radiographs should be taken for further investigation.

### **References**

- Bradley, K. 2005. Practical contrast radiography 2. Gastrointestinal studies. In Practice. 27(5): 412-417.
- Farrow, C.S. 1993. Stomach. The abdomen. In: Radiology of the Cat. St. Louis, Missouri: Mosby. 162-171.