

6-1-2010

Lateral Patellar Luxation in Three Pomeranian Dogs: A Case Report

Chalika Wangdee

Pinrath Torwattanachai

Follow this and additional works at: <https://digital.car.chula.ac.th/tjvm>



Part of the [Veterinary Medicine Commons](#)

Recommended Citation

Wangdee, Chalika and Torwattanachai, Pinrath (2010) "Lateral Patellar Luxation in Three Pomeranian Dogs: A Case Report," *The Thai Journal of Veterinary Medicine*: Vol. 40: Iss. 2, Article 12.
Available at: <https://digital.car.chula.ac.th/tjvm/vol40/iss2/12>

This Short Communication is brought to you for free and open access by the Chulalongkorn Journal Online (CUJO) at Chula Digital Collections. It has been accepted for inclusion in The Thai Journal of Veterinary Medicine by an authorized editor of Chula Digital Collections. For more information, please contact ChulaDC@car.chula.ac.th.

Lateral Patellar Luxation in Three Pomeranian Dogs: A Case Report

Chalika Wangdee^{1*} Pinrath Torwattanachai²

Abstract

Three Pomeranians with bilateral lateral patellar luxation (LPL) were present at the Small Animal Teaching Hospital, Faculty of Veterinary Science, Chulalongkorn University. Trochlear block recession was performed on all the dogs. The additional procedures including lateral retinacular desmotomy, tibial derotation, imbrication of medial retinaculum, and/or proximal tube realignment. Medial transposition of the tibial tuberosity was additionally done in one dog. Recurrent right LPL was found and corrected in one leg of the second dog. Following at least 3 months, all three dogs walked, jumped, and put weight normally on the operated legs after the operation.

Keywords: *dogs, patella, luxation, Pomeranian, recession*

¹Department of Veterinary Surgery, Faculty of Veterinary Science, Chulalongkorn University, Bangkok 10330, Thailand

²Veterinary Surgery Unit, Small Animal Teaching Hospital, Faculty of Veterinary Science, Chulalongkorn University, Bangkok 10330, Thailand

Corresponding author E-mail: *chalika_vet@hotmail.com; chalika.w@chula.ac.th*

บทคัดย่อ

รายงานสัตว์ป่วย: สะบ้าเคลื่อนออกทางด้านข้างในสุนัขพันธุ์ปอมเมอเรเนียนจำนวน 3 ตัว

ชาลิกา หวังดี^{1*} ปิ่นรัตน์ ต่อดิพนชัย²

สุนัขพันธุ์ปอมเมอเรเนียนจำนวน 3 ตัว พบอาการสะบ้าเคลื่อนออกด้านข้างทั้ง 2 ขา เข้ามารับการรักษาที่โรงพยาบาลสัตว์เล็ก คณะสัตวแพทยศาสตร์ จุฬาลงกรณ์มหาวิทยาลัย สุนัขทุกตัว ได้รับการทำศัลยกรรมโดยวิธี Trochlear block recession ร่วมกับวิธีอื่นๆ ได้แก่ Lateral retinacular desmotomy, tibial derotation, imbrication of medial retinaculum และ/หรือ Proximal tube realignment ตามความเหมาะสมในสุนัขแต่ละตัว สุนัข 1 ตัว ได้รับการย้ายกระดูก tibial tuberosity ไปทางด้านใน ผลการรักษาพบการกลับเคลื่อนที่เดิมจำนวน 1 ขาของสุนัขตัวที่สอง ซึ่งได้รับการแก้ไขใหม่ ภายหลังการติดตามผลการรักษาอย่างน้อย 3 เดือน พบว่าสุนัขทั้ง 3 ตัวสามารถเดิน กระโดด และใช้ขาจับน้ำหนักรับได้เป็นปกติภายหลังการผ่าตัด

คำสำคัญ: สุนัข สะบ้า การเคลื่อน ปอมเมอเรเนียน การเข่าร่อง

¹ภาควิชาสัตวศาสตร์ คณะสัตวแพทยศาสตร์ จุฬาลงกรณ์มหาวิทยาลัย ปทุมวัน กรุงเทพฯ 10330

²หน่วยศัลยกรรม โรงพยาบาลสัตว์เล็ก คณะสัตวแพทยศาสตร์ จุฬาลงกรณ์มหาวิทยาลัย ปทุมวัน กรุงเทพฯ 10330

*ผู้รับผิดชอบบทความ E-mail: chalika_vet@hotmail.com; Chalika.W@Chula.ac.th

Introduction

Patellar luxation is one of the most common orthopaedic disorders found in small breed dogs and results in the development of degenerative joint diseases, pain and lameness (Hulse, 1981). Though medial patellar luxation (MPL) is recognized in dogs of all sizes, it is observed more often in small breed dogs than lateral patellar luxation (LPL) which is mostly found in large breed dogs (Robin, 1990; Hayes et al., 1994; Brinker et al., 1997). In Thailand, there is high incidence of patellar luxation in the newly born dogs of small breeds and more than 87% are MPL (Wangdee et al., 2005; Wangdee and Kalpravidh, 2008).

LPL is uncommon in small breed dogs. When presented, it is a congenital disorder resulted from lateral malalignment and possibly progresses to the markedly functional impotence of the affected limbs. Compromised extensor mechanism forces the thighs outwards, laterally dislocates the tendon of the quadriceps, and promotes internal femoral torsion, medial fascia distraction, lateral fascia contraction, external rotation, and lateral deviation of the proximal tibia. The cause of this condition is still unknown but it is suggested to be related to anteversion abnormality or coxa valga of the coxofemoral joint.

The objective of this report was to illustrate the result of the LPL after correction.

Materials and Methods

Three Pomeranians with bilateral LPL were presented at the Small Animal Teaching Hospital,

Faculty of Veterinary Science, Chulalongkorn University. Conformation and gaits were observed while the dogs were walking and trotting. Both stifle joints were examined while the animal was in standing position to compare the contralateral joints and to assess the quadriceps muscle contraction. In a standing and lateral recumbent positions, the entire hind limbs were examined for the relative anatomical positions of the quadriceps, patellar ligament, trochlear sulcus, and tibial tuberosity. Femorotibial instability was assessed to rule out cranial cruciate ligament rupture.

The first case was a 2 month old female dog with grade IV bilateral LPL. Neither patellae could be manually reduced to the trochlear sulci. The tibial tuberosity rotated to 90 degrees in the right and 60 degrees in the left stifles. The second dog was a 7 month old male with grade III bilateral LPL and the tibial tuberosities rotated 30 degrees. Both patellae permanently luxated but could be manually reduced to be seated in the trochlear sulci. Laxity was presented in both coxofemoral joints. The third dog was a 1 year old female with left grade IV LPL, right grade III LPL, and non-weight bearing. In all cases, physical examination revealed pain, thigh muscle atrophy, adduction of both hock joints with toes pointing laterally, inability to extend stifle joints and bent hindlimb posture.

The lateral and ventrodorsal radiographs of the hindquarter were taken to assess the coxofemoral joints, bony deformity and degenerative changes. In the case of intermittent luxation, the radiographs were

taken while the patella was out of the trochlear sulcus in order to evaluate limb alignment (Figure 1). Skyline views of the stifle joint were made preoperatively and postoperatively to evaluate the depth and contour of the femoral trochlea (Figure 2). Radiographs of all dogs illustrated patellar luxation on the lateral site with either absent or convex trochlear sulcus.

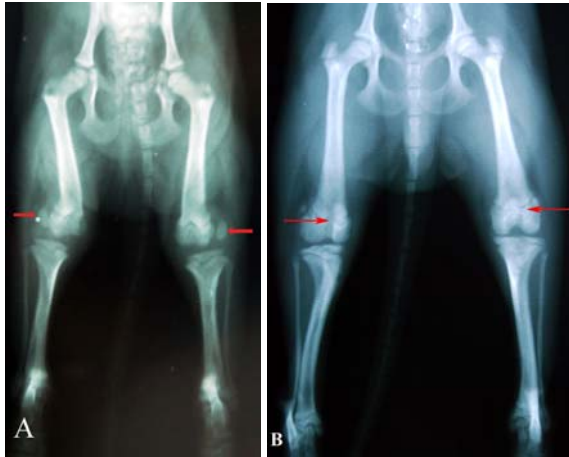

Figure 1. Ventrodorsal radiographs of both hindlimbs in the first dog: A: patella luxated laterally; B: patella stayed in the normal position 2 months after surgery (arrows).

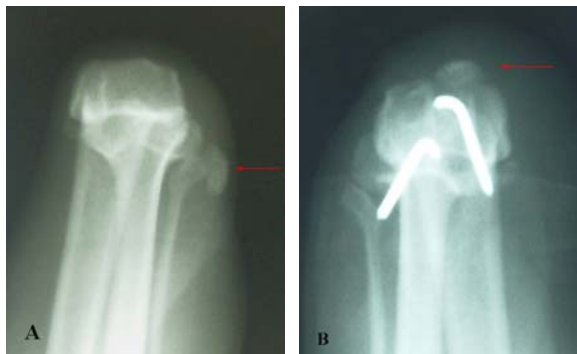

Figure 2. Skyline radiographic views of the left hindlimb (case 3) illustrated the patella luxated laterally (A) and in the trochlear sulcus after surgery (B) (arrows).

Physical examination and blood analysis were performed preoperatively. Acepromazine 0.02 mg/kg and morphine 0.5 mg/kg were administered as premedications. Fifteen-thirty minute after the premedication, anesthesia was induced with propofol to effect and maintained with isoflurane in 100% oxygen. Prophylactic cefazolin 25 mg/kg is administered intravenously.

Surgical treatment: A lateral parapatellar skin incision was made starting from the tibial tuberosity lateral to the patellar ligament and continued proximally to the patella and then, at an equal distance, along the cranial border of the femur. Arthrotomy was performed by incising the medial fascia medial to the patellar ligament, the joint capsule, the medial parapatellar fibrocartilage, the vastus medialis

muscle, and the cranial part of the sartorius muscle parallel to the patella. Tissue on the medial side of the patella was left enough for suturing.

The surgical techniques were trochlear block recession (TBR), lateral retinacular desmotomy, imbrication of the medial retinaculum, proximal tube realignment, tibial derotation and medial transposition of the tibial tuberosity. We will illustrate all in brief.

TBR was performed by using osteotome to cut a block-shaped in the femoral trochlea. Additional subchondral bone is removed by using a rongeur. Then the articular block was replaced into defect in a recessed position. Lateral retinacular desmotomy was performed by incising lateral retinaculum 3 to 5 mm from and parallel to the patella and undermining to relieve tension on the lateral site. Imbrication of the medial retinaculum was performed by suturing the medial retinaculum with absorbable suture (polyglactin) and overlapping pattern.

Proximal tube realignment for LPL was performed after the joint capsule had been closed. Subcutaneous tissue anterior, lateral, and medial to the patella was dissected to visualize the medial and lateral retinacula which were incised 3 to 5 mm from and parallel to the patella. The caudal flap of the lateral retinaculum was undermined to relieve tension on the lateral site. The caudal flap of the medial retinaculum was suture with absorbable suture (polyglactin) and simple interrupted pattern to the cranial flap of the lateral retinaculum adjacent to the patella (Wangdee and Kalpravidh, 2008)

Tibial derotation was performed by placement of heavy nonabsorbable suture material from lateral fabella to the tibial tuberosity. Medial transposition of the tibial tuberosity was performed with the aid of osteotome to remove the insertion site of the patellar tendon and its fixation to facilitate stable seating of the tuberosity in a medial position with one to two small Kirschner wires.

A combination of surgical techniques was performed, based on the depth of trochlear sulcus and the alignment of the patella, patellar ligament, tibial tuberosity and foot point. TBR was performed on all dogs. Additional techniques in the first dog with grade IV of both LPL were lateral retinacular desmotomy, and tibial derotation. In the second dog, proximal tube realignment was performed on the left grade III LPL and 4 weeks later on the right grade III LPL. Recurrent right LPL was found 5 days after the operation and corrected by TBR, tibial derotation and imbrication of the medial retinaculum. In the third dog, lateral retinacular desmotomy, medial transposition of the tibial tuberosity and imbrication of the medial retinaculum were performed on the left grade IV LPL and 15 weeks later on the right grade III LPL. Erosion of both trochlear ridges was found in this dog with an absent trochlear sulcus (Figure 3). Physiotherapy procedures were performed one or

two weeks before and after the operation. After the operation, all the dogs were restricted to a short leash walk for 4-6 weeks and a passive range of exercise was performed several times daily as long as necessary to maintain joint range of motion and accelerate return to function. Electronic nerve stimulator was used in the third case to relief of musculoskeletal pain.

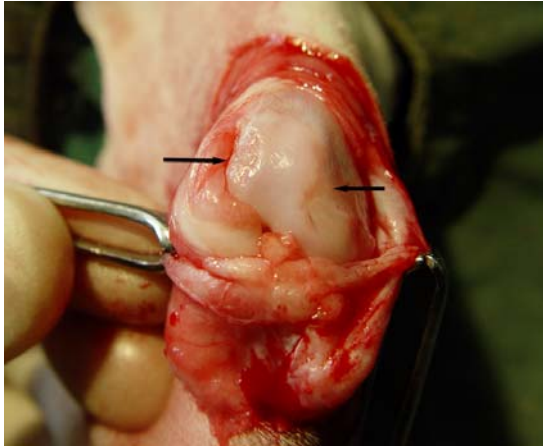


Figure 3. Erosion of both trochlear ridges of case 3 (arrows)

Results and Discussion

The first dog could walk but tremble within 2 days after the operation. Weight bearing improved within 10 days. The patient could walk properly and jump three weeks of the operation. Radiographic examination revealed a normal position of the patella. The second dog started using its left leg 1 day after the operation and his weight bearing improved at 10 days after operation while preoperative abnormal laxity of the coxofemoral joints remained. LPL recurred at the right stifle 5 days after the operation and was corrected 10 days later by TBR to widen and deepen the trochlear sulcus. Tibial derotation was used to correct quadriceps alignment, and imbrication of the medial retinaculum to increase tension on the medial side. Weight bearing on the right leg started 5 days after the correction and was fully recovered 5 days later. One month after the operation, weight bearing and the gait of the left leg was normal. However, muscle atrophy was seen in the right leg. Three months after the operation, both patellae remained in the trochlear sulci and the gait of both limbs was normal.

After the correction of the left grade IV luxation in the third dog, internal rotation of the hock joint was detected and non-weight bearing was still observed. Splint for stabilization of the hock joint was employed for 4 days and passive range of motion (PROM) was followed during non-weight bearing. One month after the operation, electrical stimulation of the gastrocnemius and hamstring muscles was done. Rehabilitations at home by bandage, electrical stimulation, PROM and stretching the animal leg were suggested to the owner. Although weight

bearing of the left leg was normal, a short gait was seen 15 weeks after the operation when the right grade III LPL was corrected. Six weeks after the operation on the right s, the weight bearing on both hind limbs was normal but the limbs could not be fully extended. However, both patellae were in the trochlear sulci and could be palpated without pain.

The trochlear sulcus of case 1 was shallower than normal which needed trochleoplasty. Chondroplasty was not feasible in this case because the trochlear sulcus was too narrow to make a cartilage flap. TBR was suitable for this case because it could increase the proximal patellar depth and patellar articular contact by recessing the trochlea. After the TBR, the larger percentage of trochlear surface area provided the greater resistance of the patella to luxate in an extended position as compared with trochlear wedge recession (Johnson et al., 2001). Tibial derotation was performed on this dog because the growth plate was still action. The tibial tuberosity would be in a normal position if the alignment of quadriceps tendon is appropriately adjusted and the trochlear sulcus is deep enough to secure the patella in place.

Recurrent PL is common complication which is occurred 8 % (Arthurs and Langley-Hobbs, 2006). We recommend performing a second correction in case 2 because the LPL had been presented the severe problems including lameness, deformity of entire hindlimb and gait abnormality.

Selection of the surgical treatment of patellar luxation is based on age of the animal and duration of the luxation. In young dogs, bone is not fully developed and limb deformity is minimal. If the alignment of bone and patellar ligament is corrected, limb alignment will be normal. Muscular contracture in young dogs is so minimal that muscle and ligament can get their function back to normal faster and easier than older dogs. The first case had limb muscle function and weight bearing returning to normal quite rapidly. In the third case with more severe grade of PL and erosion of both trochlear ridges requiring more invasive surgical technique had slow recovery of the weight bearing and needed intensive rehabilitation.

Conclusion

The three cases of LPL had stiffness and gait abnormality because muscles on the lateral side are stronger and thicker than those on the medial side. So muscle pull on the lateral side is greater than the medial side. Muscle atrophy of the limb secondary to non-weight bearing is another cause of hip laxity and gait abnormality so rehabilitation need to increase the muscle mass.

References

- Arthurs, G.I. and Langley-Hobbs, S.J. 2006. Complications associated with corrective

- surgery for patellar luxation in 109 dogs. *Vet. Surg.* 35(6): 559-566.
- Brinker, W.O., Piermattei, D.L. and Flo, G.L. 1997. The Stifle Joint. In: *Handbook of Small Animal Orthopaedics and Fracture Repair*. 3rd ed. Philadelphia: Saunders. 516-580.
- Hayes, A.G., Boudrieau, R.J. and Hungerford, L.L. 1994. Frequency and distribution of medial and lateral patellar luxation in dogs: 124 cases (1982-1992). *J. Am. Vet. Med. Assoc.* 205(5): 716-720.
- Hulse, D.A. 1981. Pathophysiology and management of medial patellar luxation in the dog. *Vet. Med. Small Anim. Clin.* 76: 43-51.
- Johnson, A.L., Probst, C.W., Decamp, C.E., Rosenstein, D.S., Hauptman, J.G., Weaver, B.T. and Kern, T.L. 2001. Comparison of trochlear block recession and trochlear wedge recession for canine patellar luxation using a cadaver model. *Vet. Surg.* 30(2): 140-150.
- Robins, G.M. 1990. The canine stifle joint. In: *Canine Orthopedics*. 2nd ed. W.G. Whittick (ed.) Philadelphia: Lea & Febiger. 693-760.
- Wangdee, C. and Kalpravidh, M. 2008. Tube realignment for patellar luxation repair in dogs. *Thai J. Vet. Med.* 38(2): 39-44.
- Wangdee, C., Soontornvipart, K. and Chuthatep, S. 2005. The study of the canine patellar luxation surgical treatments. *J. Thai Vet. Pract.* 17(4): 13-25.

