

10-1-1984

Toxic epidermal necrolysis in a premature baby

Suwimol Sanpavat

Saree Chittinand

Paiboon paisunthornsuk

Prapai Pongprasit

Follow this and additional works at: <https://digital.car.chula.ac.th/clmjournal>



Part of the [Medicine and Health Sciences Commons](#)

Recommended Citation

Sanpavat, Suwimol; Chittinand, Saree; paisunthornsuk, Paiboon; and Pongprasit, Prapai (1984) "Toxic epidermal necrolysis in a premature baby," *Chulalongkorn Medical Journal*: Vol. 28: Iss. 10, Article 12.
DOI: 10.58837/CHULA.CMJ.28.10.12

Available at: <https://digital.car.chula.ac.th/clmjournal/vol28/iss10/12>

This Case Report is brought to you for free and open access by the Chulalongkorn Journal Online (CUJO) at Chula Digital Collections. It has been accepted for inclusion in Chulalongkorn Medical Journal by an authorized editor of Chula Digital Collections. For more information, please contact ChulaDC@car.chula.ac.th.

Toxic epidermal necrolysis in a premature baby

Suwimol Sanpavat*

Saree Chittinand*

Paiboon Paisunthornsuk**

Prapai Pongprasit*

สุวิมล สรรพวัฒน์, สำหรั จิตตินันท์, ไพบุญ ไพสุนทรสุข, ประไพ
พงษ์ประสิทธิ์. Toxic epidermal necrolysis ในเด็กคลอดก่อนกำหนด. จุฬาลงกรณ์เวชสาร 2527 ตุลาคม; 28 (10) : 1187-1195

รายงานเด็กคลอดก่อนกำหนด 1 ราย อายุ 22 วัน สะดืออักเสบ ได้รับการรักษาด้วย Cloxacillin และ gentamicin เด็กมีผื่นแดงบริเวณลำตัว ขาและลามต่อไปยังหน้า ผ่ามือและฝ่าเท้า แผลบริเวณเย็บในปาก ต่อมาผิวหนังลอกเน่า และมีน้ำเหลืองไหลซึมได้รับการรักษาแบบประคับประคอง รักษาตามอาการ ยาปฏิชีวนะหลายชนิด และสเตียรอยด์ แต่อาการไม่ดีขึ้น ผลจากการตรวจชิ้นเนื้อ และตรวจศพวินิจฉัยว่าเป็นโรค Toxic epidermal necrolysis ซึ่งมีอาการทางคลินิกคล้ายคลึงกับ Staphylococcal scalded skin syndrome แต่ภาวะทั้งสองนี้จะแยกจากกันได้โดย histopathology.

* Department of Pediatrics, Faculty of Medicine, Chulalongkorn University.

** Department of Pathology, Faculty of Medicine, Chulalongkorn University.

Toxic epidermal necrolysis (TEN) and the scalded skin syndrome are reactions of the skin with acute exfoliation of all or part of the epidermis following exposure to several causative agents. These two conditions have distinct pathologic features. TEN is rarely seen in twin prematures, involving only one baby. We wish to report the clinical presentation of a premature baby who developed TEN and review the differences between these two conditions.

Case report

A 1300 grams twin "A" male infant was born to a G₁P₀ 30-years-old mother by vaginal delivery after 16 hours of the premature rupture of the membrane. The mother did not receive any medication and her complete blood count both prior to and after delivery were within normal limits. The placenta appeared to be monochorionic. The Apgar scores were 8 & 9 at 1 and 5 minutes respectively. Physical examination revealed a premature infant, of about 33 weeks gestation, who was in acute respiratory distress. Oxygen had been given for five consecutive days for the treatment of respiratory distress syndrome. Jaundice was first noticed on the second day and was treated accordingly.

Due to the severe illness with marked leukopenia of his identical twin, investigation and treatment for septicemia were carried out on the forth day of life. His complete blood count showed leukopenia (WBC 1,200/mm³), but normal differential and platelet counts. Antibiotics and buffy coat transfusion were

given. The cultures from blood and cerebrospinal fluid grew no organism. He remained clinically active and oral feeding was started on the 6th day.

He had been well fed until the 22nd day of age when he became dusky in colour, had vomiting, and apnea. Physical examination disclosed a hypotonic infant with abdominal distension, inflammation of the umbilicus and palpable liver and spleen. Cloxacillin and Gentamicin were given for omphalitis and possible septicemia. The examination of serum electrolyte, CSF and chest roentgenogram were normal. The nasopharyngeal culture grew *H. influenzae*, but the urine and CSF were sterile. The complete blood count were within normal limit except for thrombocytopenia (platelet count 37,000/mm³). Two days later he was noted to have faint erythematous maculopapular rashes over the body and lower extremities. His palms and soles were shiny and the eyelids looked puffy. The inflammation of the umbilicus subsided after 3 days of antimicrobial therapy, but the child became severely ill and antibiotics were changed to cefotaxime and amikacin. Hyponatremia, leukopenia, thrombocytopenia and sclerema developed. Over the next 48-72 hours the erythematous rashes became confluent, and progressed to the face, palms and soles. Petechiae were prominent when the platelet dropped to 3,000. The following day there were dry cracking of the lips, small ulcers in the mouth and conjunctivitis with purulent discharge. There was no bullous formation but

Nikolski's sign was not tested. The skin biopsy was done and intravenous hydrocortisone was given with the provisional diagnosis of toxic epidermal necrolysis. On the next day there was some peeling of the skin on the face and the flank, leaving the underlying denuded areas oozing with serum. The raw surface was treated with NSS wet-dressing using aseptic precaution. When 2 out of the 3 bottles of blood culture were known to grow *Staphylococcus*, coagulase test negative, cefotaxime was changed to cephalosporin according to the sensitivity. The other treatments included packed red cell, buffy coat, fresh frozen plasma, platelet transfusion, oral mycostatin for the

candida found in stool, and correction of hypernatremia. His WBC was only 2,000/mm³ with agranulocytosis despite extensive therapy. He continued to do poorly with progressive necrosis of the epidermis, of the groin and both lower extremities and expired at 34 days of age.

Skin biopsy showed early necrosis of the epidermis with superficial lymphohistiocytic infiltration of the dermal vessels.

Autopsy revealed necrosis of the mucosa and skin all over the body with pseudohyphae and blastospores infiltrating through the dermis. The lungs showed interstitial pneumonia. These conditions attributed to the death of this patient.

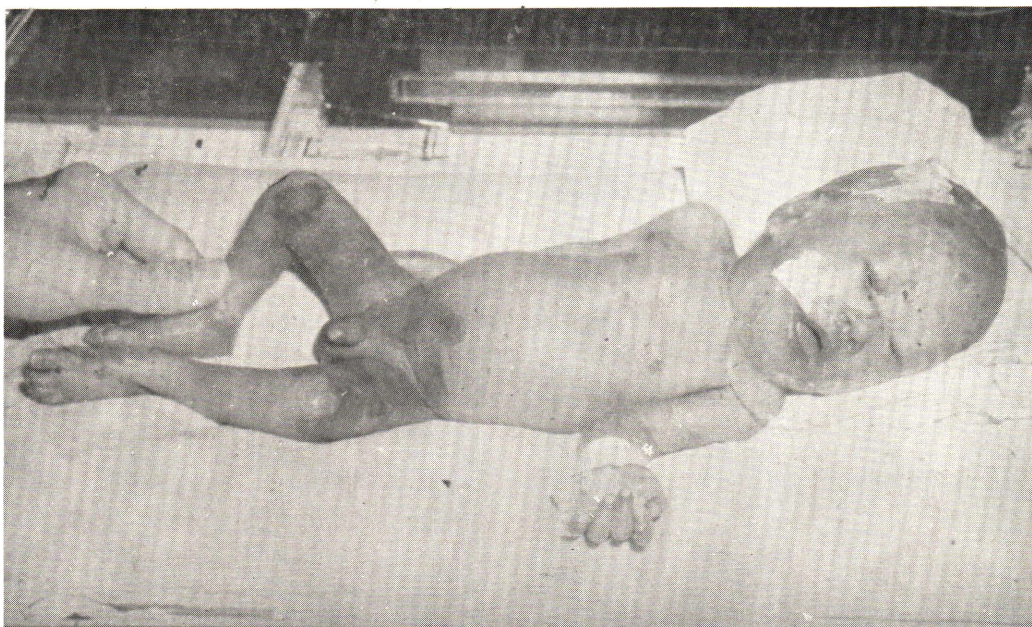


Fig. 1 Epidermal necrosis of the diaper area, buccal mucosa ulceration and edematous eyelids.

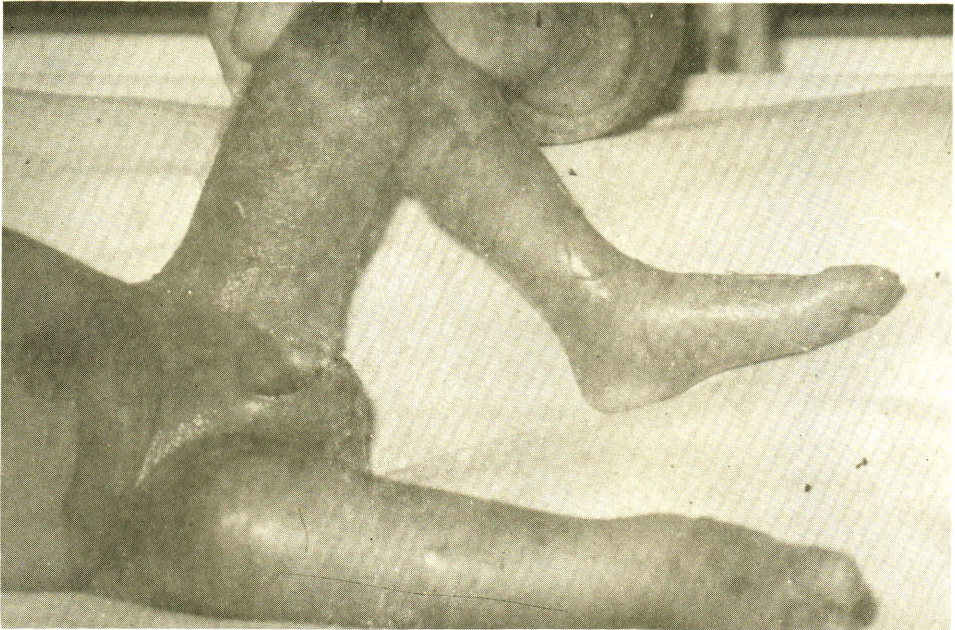


Fig. 2 Edema and epidermal necrosis of the groin and lower extremities.

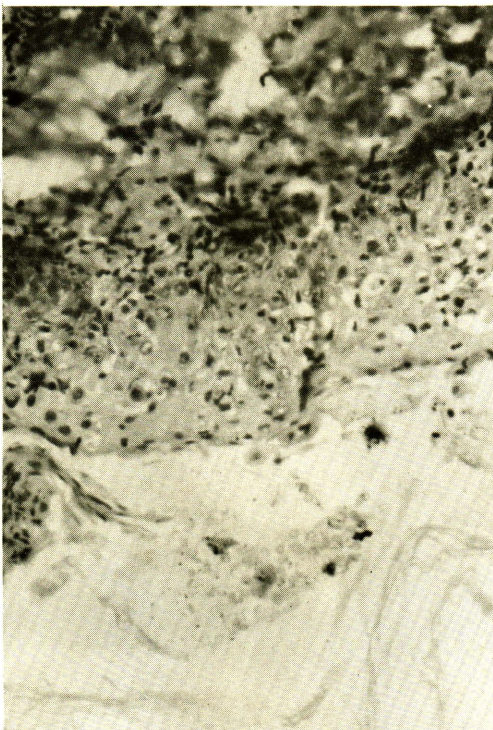


Fig. 3 Skin biopsy showed the epidermis consisting mostly of the keratinocytes with eosinophilic necrosis. The upper dermis was infiltrated with inflammatory cells (H&E $\times 100$)

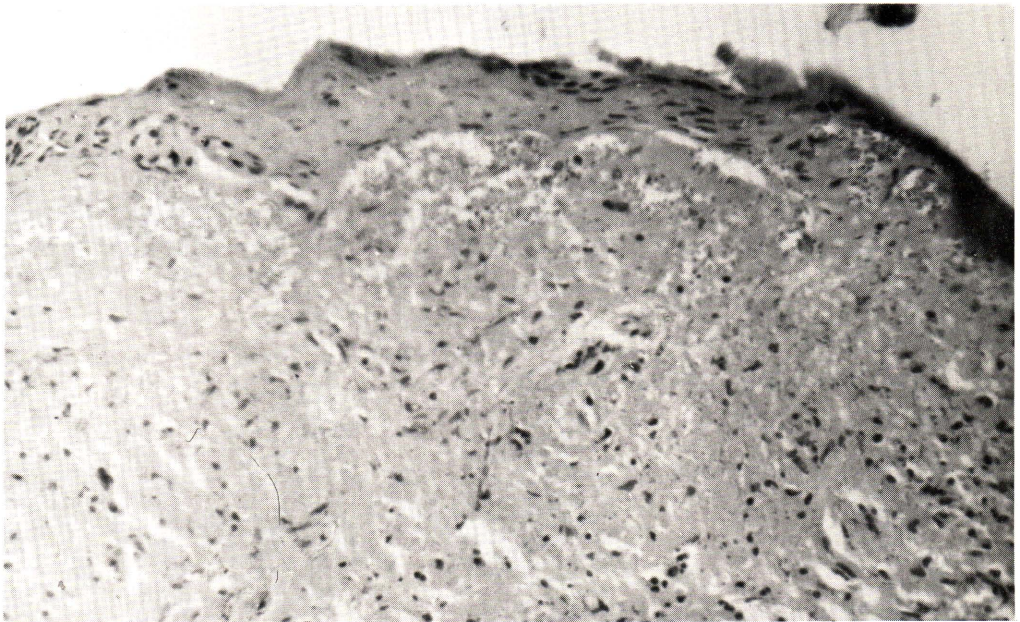


Fig. 4 Histopathology of the skin from the autopsy demonstrating the eosinophilic necrosis of the whole thickness of the epidermis with subepidermal cleft. Note the invasion of the upper dermis by the inflammatory cells and blastospores. (H & E \times 40)

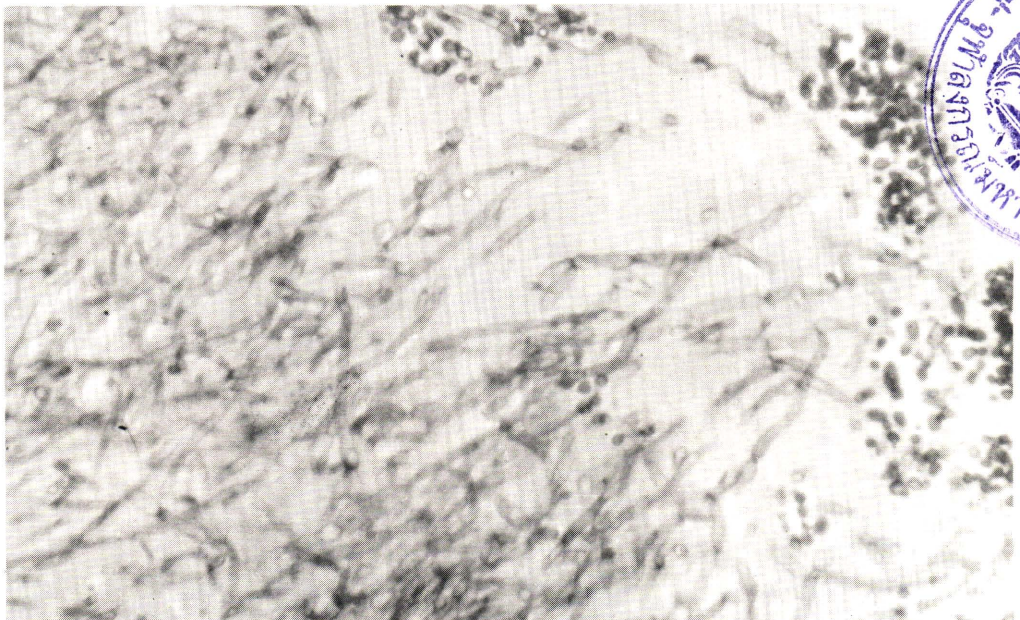


Fig. 5 Silver stain demonstrating yeast forms and pseudohyphae throughout the necrotic areas of the epidermis and dermis.

Discussion

The scalded skin syndrome and TEN were terminologies used interchangeably in the past. Historically, the scalded skin syndrome or Ritter's disease was described in the neonate by Ritter von Rittershain in 1878.⁽¹⁾ Several other probable cases in children and adults were reported.⁽²⁻⁴⁾ Lyell in 1956 described the eruption resembling the scalding of skin in adults and suggested the name "toxic epidermal necrolysis".⁽⁵⁾

The disease is classified into bacterial, drug-induced, miscellaneous and idiopathic categories.⁽⁶⁾ In children of less than 5 years, it is usually caused by *Staphylococcus aureus*,⁽⁷⁻¹⁰⁾ hence the name Staphylococcal scalded skin syndrome (SSSS). The lesion in the adult is generally considered to be a drug-induced disease,⁽⁸⁾ although both causative agents have been found in all age groups.^(5,8,9,11,12,13,14) Melish and Glasgow have proved that SSSS is caused by Staphylococcal phage group 2 which produces toxin termed epidermolysin or exfoliative toxin.⁽¹⁶⁾ Sarai has shown that group 1 and 3 can produce the toxin as well as group 2.⁽¹⁷⁾ The organisms are frequently isolated from the nasopharynx, eyes, oropharynx, skin, ears and rectum. Culture from the blood is frequently sterile. Other strains of bacteria that have been obtained in association with this disease are *Strepto-*

coccus viridans,⁽¹⁵⁾ *Haemophilus influenzae* from a nasopharyngeal swab and *Staphylococcus albus* from the blister fluid.⁽⁸⁾ Neff et al have attributed this syndrome to measles.

Drugs that are thought to be responsible for the development of the scalded skin are penicillin and its derivatives, sulfur drugs, pyrazolone derivatives, aspirin or methyl salicylate, all barbiturates, streptomycin, polio vaccine, all tetracyclines, phenacetin or acetanilid, all antihistamines, phenolphthalein and meperidine.⁽⁹⁾ An outbreak of boric acid poisoning caused a lesion clinically indistinguishable from SSSS of the newborn infant.⁽¹⁸⁾ Lyell described the miscellaneous group of TEN as an incident during the course of another illness, such as lymphoma, septicemia, for which the patients also received various medications. The idiopathic group of TEN is found mostly among elderly women without any identifiable cause.⁽⁸⁾

Because of the proven differences in histopathology and avoidance of the confusion between these two separate entities, Elias et al preferred to call the usual nonstaphylococcal adult form TEN, and the Staphylococcal disease SSSS.⁽⁷⁾ In this report, we adopt these terminologies.

Clinically SSSS and TEN are almost indistinguishable. In both conditions, onset is usually abrupt with areas of erythema on face, trunk and extremities. The erythema blanches with

pressure and the skin is tender to touch. A positive Nikolsky's sign can be elicited. Within 24-48 hours the involved areas become wrinkled and flat bullae containing clear fluid appear. The mucous membrane is involved more frequently in TEN than in SSSS.⁽⁷⁾ There may be edema especially of the eyelids and mouth in SSSS.⁽²⁰⁾ Over a period of days the skin exfoliate, leaving red denuded areas. In SSSS the bright-red denuded areas dry up quickly and become tan or bronze discolouration. Recovery, without scarring, accompanied by postinflammatory desquamation is usually completed in 5-7 days.⁽⁷⁾ On the other hand, the course of TEN is more protracted. Because of the depth of the skin involvement, TEN causes more fluid loss and electrolyte imbalance; and the survivor is left with scarring.

Differentiation between SSSS and TEN is possible by histopathology. Epidermolytic toxin produced by group 2 Staphylococci results in cleavage in the upper malpighian and granular layers of the epidermis^(18,19) with no inflammatory cells. Nonstaphylococally induced TEN causes necrolysis of the epidermis with dermo-epidermal separation and inflammatory cells.⁽¹²⁾ Rapid differentiation between these two conditions should be carried out for initiation of therapy. Amon et al have presented two such methods.⁽¹²⁾ First by histological examination of a frozen

section of peeled skin obtained from a fresh lesion and secondly by performing a Tzanck preparation on the denuded area.

Differential diagnosis of TEN or SSSS includes bullous erythema multiforme, Stevens-Johnson syndrome, boric acid toxicity, thermal burn, and rarely, cutaneous candidosis.⁽²⁰⁾ In the neonate, congenital syphilis, congenital ichthyosiform erythroderma, epidermolysis bullosa and Leiner's disease might be considered.

Although SSSS is probably self-limited,⁽¹⁸⁾ it is generally recommended that penicillinase-resistant penicillin be given to abort toxin elaboration at the earliest stage.⁽²¹⁾ Steroids are contraindicated.⁽²²⁾ Treatment of TEN includes discontinuation of the offending agents and correction of fluid and electrolyte imbalance.⁽⁷⁾ Steroid may be necessary.⁽¹²⁾ The skin lesion should be treated as an extensive second degree burn.⁽⁷⁾ The mortality rate is 25-50% in TEN. Although SSSS has high incidence of spontaneous recovery,⁽⁷⁾ fatality particularly in the newborn infant has been attributed to overwhelming sepsis and fluid-electrolyte imbalance. Recovery in SSSS is usually without scarring, while in TEN There may be scarring, milia, atrophy or pigmentary residua.⁽⁷⁾

From the histopathology of the cleavage plane, we concluded that our patient had TEN. It was not possible

to confirm that the lesion resulted from drug-induction because direct or indirect immunofluorescent stain for the antibody and complements was not done. The patient was a compromised host who also had leukopenia and agranulocytosis; the disease process was devastating. Septicemia, secondary fungal infection and fluid and electrolyte imbalance contributed to the fatality in this patient.

Conclusion

A 3 week-old premature infant who developed TEN is reported. Supportive, symptomatic and specific treatments proved futile in this patient. The histopathology from the skin biopsy and autopsy confirmed the diagnosis of toxic epidermal necrolysis.

Acknowledgement

The authors thank Dr. Prasit Futrakul for his support and editorial assistance.

References

1. Rasmussen JE. Toxic epidermal necrolysis. Arch Dermatol 1975 Sept; 111(9) : 1135-1139
2. Beare M. Toxic epidermal necrolysis. Arch Dermatol 1962 Nov; 86(11) : 638-653
3. Baird RL, Reichelderfer TE. Toxic epidermal necrolysis (Scalded skin syndrome). Clin Pediatr 1963 Jan; 2(1) : 16-20
4. Freedberg IM, Berg RB. Toxic epidermal necrolysis. N Engl J Med 1964 Sept; 271 (12) : 616-617
5. Lyell A. Toxic epidermal necrolysis : eruption resembling scalding of skin. Br J Dermatol 1956 Nov; 68(5) : 355-361
6. Lyell A. A review of toxic epidermal necrolysis in Britain. Br J Dermatol 1967 Dec ; 79 (6) : 662-671
7. Elias PM, Fritsch P, Epstein EH. Staphylococcal scalded skin syndrome : clinical features, pathogenesis and recent microbiological and biochemical developments. Arch Dermatol 1977 Feb; 113(2) : 207-219
8. Curran JP, Al-Salihi FL. Neonatal staphylococcal scalded skin syndrome : Massive outbreak due to an unusual phage type. Pediatrics 1980 Aug; 66(2) : 285-290
9. Lowney ED, Baublis JU, Kreye GM, Harrell ER, McKenzie AR. The scalded skin syndrome in small children. Arch Dermatol 1967 Apr; 95(4) : 359-369
10. Tyson RG, Ushinshi SC, Kisilevsky R. Toxic epidermal necrolysis (the scalded skin syndrome). Am J Dis Child 1966 Apr; 111(4) : 386-392
11. Levine G, Norden CW. Staphylococcal scalded-skin syndrome in an adult. N Engl J Med 1972 Dec 28; 287(26) : 1339-1340

12. Amon RB, Dimond RL. Toxic epidermal necrolysis : rapid differentiation between staphylococcal and drug-induced disease. Arch Dermatol 1975 Nov; 111 (11) : 1433-1437
13. Epstein EH, Flynn P, Davis RS. Adult toxic epidermal necrolysis with fatal staphylococcal septicemia. JAMA 1974 Jul 22; 229(4) : 425-430
14. Mazella JP, Hall CB, Green JL, Mc Meekin TO. Toxic epidermal necrolysis in childhood : differentiation from staphylococcal scalded skin syndrome. Pediatrics 1980 Aug; 66(2) : 291-294
15. Catto JVF. Toxic epidermal necrolysis occurring in a child. Br Med J 1959 Sept 26; 2(5151) : 544-545
16. Melish ME, Glasgow LA. The staphylococcal scalded-skin syndrome : development of an experimental model. N Engl J Med 1970 May 14; 282(20) : 1114-1119
17. Sarai Y, Nakahara H, Ishileawa T. A bacteriological study on children with staphylococcal toxic epidermal necrolysis in Japan. Dermatologica 1977; 154 : 161
18. Rubenstein AD, Musher DM. Epidermic boric acid poisoning simulating staphylococcal toxic epidermal necrolysis of the newborn infant : Ritter's disease. J Pediatr 1970 Nov; 77(5) : 884-887
19. Lillibridge CB, Melish ME, Glasgow LA. Site of action of exfoliative toxin in the staphylococcal scalded skin syndrome. Pediatrics 1972 Nov; 50(5) : 728-738
20. Margileth AM. Scalded skin syndrome : diagnosis, differential diagnosis and management of 42 children. South Med. J 1975 Apr; 68(4) : 447-454
21. Melish ME, Glasgow LA. Staphylococcal scalded skin syndrome : the expanded clinical syndrome. J. Pediatr 1971 Jun; 78 (6) : 958-967