

12-1-2009

## Ophthalmology Snapshot

Nalinee Tuntivanich

Follow this and additional works at: <https://digital.car.chula.ac.th/tjvm>



Part of the [Veterinary Medicine Commons](#)

---

### Recommended Citation

Tuntivanich, Nalinee (2009) "Ophthalmology Snapshot," *The Thai Journal of Veterinary Medicine*: Vol. 39: Iss. 4, Article 9.

DOI: <https://doi.org/10.56808/2985-1130.2197>

Available at: <https://digital.car.chula.ac.th/tjvm/vol39/iss4/9>

This Other is brought to you for free and open access by the Chulalongkorn Journal Online (CUJO) at Chula Digital Collections. It has been accepted for inclusion in The Thai Journal of Veterinary Medicine by an authorized editor of Chula Digital Collections. For more information, please contact [ChulaDC@car.chula.ac.th](mailto:ChulaDC@car.chula.ac.th).

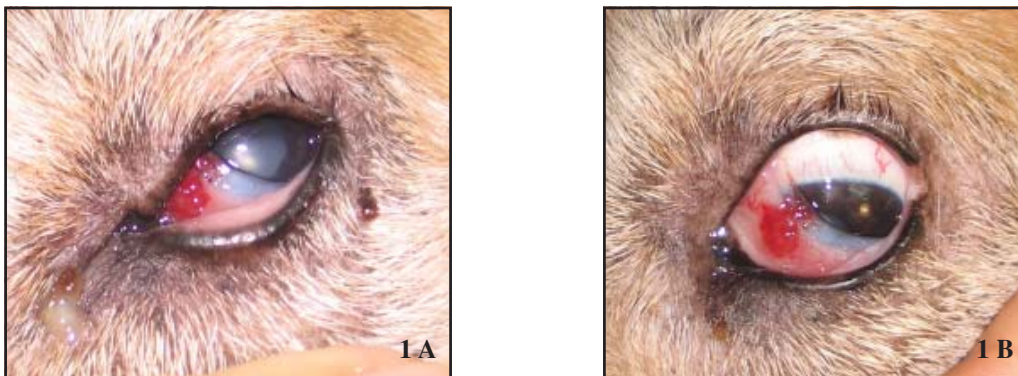
## Ophthalmology Snapshot

Nalinee Tuntivanich

### History

A 10 yr-old female mixed breed dog was presented at the Small Animal Teaching Hospital, Chulalongkorn University with a proliferative, bright red mass at the outer surface of the left nictitating membrane (Figure 1A). The mass had been presented for several months and slowly enlarged lately. Neither ocular pain nor hemorrhage was

observed. Fluorescein staining test revealed no stromal corneal ulcer. A combination of antibiotic and corticosteroid ointment was topically administered twice daily for three consecutive days prior to surgery. The mass appeared less proliferative at day of surgery (Figure 1B).



**Figure 1.** Photograph of the left eye at (A) day of ophthalmic examination revealing a proliferative, bright red mass at the nictitating membrane, and (B) day of surgery (the dog was under general anesthesia).

### Questions

Give your tentative diagnosis, treatment of choice and prognosis?

(For better quality, figures can be viewed in the TJVM website.)

Please turn to the next page for answers .....

## Answers

Tentative diagnosis: tumor of the nictitating membrane

Treatment of choice: surgical excision (additional/alternative treatment includes laser, radiation, electrotherapy, cryotherapy)

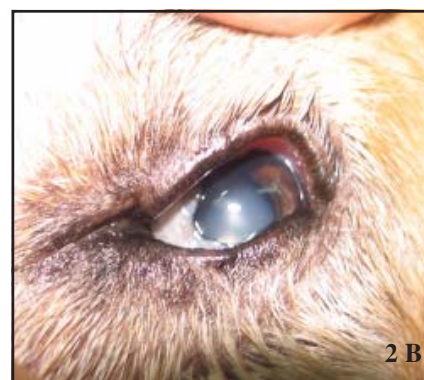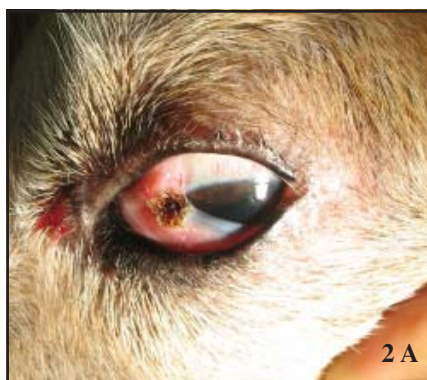Prognosis: based on several factors such as type and size of the tumor, method of treatment, area and depth of excision, etc

## Additional information

Treatment of this case: the tumor was surgically removed. Electrotherapy was applied afterward at wider region around the surgical site.

Final histopathological diagnosis: hemangioma

No evidence of recurrence has been noted until the last ophthalmic examination at 5 months after treatment.



**Figure 2.** Photograph of the left eye at (A) day of surgery after the mass was surgically excised followed by electrotherapy and (B) two weeks after surgery.

## Comments

Tumor of vascular endothelial origin is common in dogs. Hemangioma accounts for approximately 2% of conjunctival tumor in canine. Average age of onset is 8.6 years. Although there is no gender predilection, female dogs may have higher risk since level of estrogen was reported to be elevated in the blood of hemangioma patients. The leading edge of the nictitating membrane is the most common site of involvement. Dogs that spend great amount of time outdoors increase risk to develop this type of tumor. There is a report indicating that there is an expression of proteins potentially altered by UV exposure in canine hemangioma as well as hemangiosarcoma. Diagnosis can be made by typical clinical appearance; however biopsy is required for definitive diagnosis. Surgical excision (with/without additional treatment) may be curative, though recurrence is still possible.

Prognosis is good if the tumor is small and limited to the nictitating membrane, and wide surgical excision achieves the tumor-free margin. Risk of metastasis is low.

## References

- Brahmasa, A., Tuntivanich, N., Tuntivanich, P. and Rungsipat R. 2006. Hemangiosarcoma of the nictitating membrane as seen in two Great Danes (a case report). *Thai. J. Vet. Med.* 36(2): 49-53.
- Pirie, C.G., Knollinger, A.M., Thomas, C.B. and Dubielzig R.R. 2006. Canine conjunctival hemangioma and hemangiosarcoma: a retrospective evaluation of 108 cases (1989-2004). *Vet. Ophthalmol.* 9(4): 215-226.
- Chandler, H.L., Newkirk, K.M., Kusewitt, D.F., Dubielzig, R.R. and Colitz, C.M.H. 2009. Immunohistochemical analysis of ocular hemangionas and hemangiosarcomas in dogs. *Vet. Ophthalmol.* 12(2): 83-90.