

12-1-2009

Efficacy of Various Strains of Infectious Bronchitis Vaccine against Nephropathogenic Infectious Bronchitis Virus Isolated from Chickens in Thailand

Tawatchai Pohuang

Kanlaya Chuachan

Niwat Chansiripornchai

Jiroj Sasipreeyajan

Follow this and additional works at: <https://digital.car.chula.ac.th/tjvm>



Part of the [Veterinary Medicine Commons](#)

Recommended Citation

Pohuang, Tawatchai; Chuachan, Kanlaya; Chansiripornchai, Niwat; and Sasipreeyajan, Jiroj (2009) "Efficacy of Various Strains of Infectious Bronchitis Vaccine against Nephropathogenic Infectious Bronchitis Virus Isolated from Chickens in Thailand," *The Thai Journal of Veterinary Medicine*: Vol. 39: Iss. 4, Article 4.

Available at: <https://digital.car.chula.ac.th/tjvm/vol39/iss4/4>

This Article is brought to you for free and open access by the Chulalongkorn Journal Online (CUJO) at Chula Digital Collections. It has been accepted for inclusion in The Thai Journal of Veterinary Medicine by an authorized editor of Chula Digital Collections. For more information, please contact ChulaDC@car.chula.ac.th.

Efficacy of Various Strains of Infectious Bronchitis Vaccine against Nephropathogenic Infectious Bronchitis Virus Isolated from Chickens in Thailand

**Tawatchai Pohuang¹ Kanlaya Chuachan¹
Niwat Chansiripornchai² Jiroj Sasipreeyajan^{2*}**

Abstract

One hundred, 1 week old, female broiler chickens were divided into 5 groups, 20 chickens in each. Each group was vaccinated with a different strain of infectious bronchitis vaccine; Ma5, H120 and a local strain produced by the Department of Livestock Development for groups 3, 4 and 5, respectively. All the vaccinated chickens received intraocular vaccine at 1 week old. The chickens in groups 1 and 2 served as a negative control and a positive control group, respectively. All the chickens were weighed at 1, 4 and 6 weeks old and challenged at 4 weeks old with nephropathogenic infectious bronchitis virus isolate THA001. Clinical signs and mortality rates were observed for 2 weeks post-challenge. Serological responses were determined at 1, 2, 3, 4, 5 and 6 weeks old. The results revealed that the body weight of chickens among the vaccinated groups was not significantly different ($p>0.05$) both before and after challenge but the body weight of chickens in the vaccinated group was significantly higher than the chickens in the positive control group ($p<0.05$). After challenge, the mortality rate of the chickens in groups 3, 4 and 5 was significantly lower than that of the positive control group ($p<0.05$). The serological response of chickens in the vaccinated groups at 2 weeks post-challenge was significantly higher than that of the positive control group ($p<0.05$).

Keywords : broiler chickens, nephropathogenic infectious bronchitis virus, vaccine

¹Department of Veterinary Medicine, Faculty of Veterinary Medicine, Khon Kaen University, Khon Kaen 40002, Thailand

²Department of Veterinary Medicine, Faculty of Veterinary Science, Chulalongkorn University, Bangkok 10330, Thailand

*Corresponding author Email: jiroj.s@chula.ac.th

บทคัดย่อ

ประสิทธิภาพของวัคซีนป้องกันโรคหลอดลมอักเสบติดต่อสเตรนต่างๆ ต่อการป้องกันโรคหลอดลมอักเสบติดต่อชนิดที่ทำให้เกิดรอยโรคที่ไตที่แยกได้จากไก่ป่วยในประเทศไทย

ชัชชัย โพธิ์เสียง¹ กัลยา เจือจันทร์¹ นิวัตร จันทร์ศิริพรชัย² จิโรจ ศศิปรีย์จันทร์^{2*}

ไก่เนื้อเพศเมีย อายุ 1 สัปดาห์ จำนวน 100 ตัว แบ่งออกเป็น 5 กลุ่มๆ ละ 20 ตัว กลุ่มที่ 3-5 ได้รับวัคซีนป้องกันโรคหลอดลมอักเสบติดต่อสเตรนต่างๆ คือ Ma5, H120 และวัคซีนที่ผลิตโดยกรมปศุสัตว์ตามลำดับ โดยการหยอดตา ไก่กลุ่มที่ 1 เป็นกลุ่มควบคุมผลลบ และกลุ่มที่ 2 เป็นกลุ่มควบคุมผลบวก เมื่อไก่อายุ 4 สัปดาห์ ให้เชื้อพิษทาบด้วยเชื้อไวรัสหลอดลมอักเสบติดต่อชนิดที่ทำให้เกิดรอยโรคที่ไตที่แยกได้จากไก่ป่วยในท้องที่ของประเทศไทย (THA001) สังเกตอาการป่วยและอัตราการตายนาน 2 สัปดาห์ ชั่งน้ำหนักไก่เมื่อไก่อายุ 1, 4 และ 6 สัปดาห์ เจาะเลือดเพื่อตรวจหาแอนติบอดีต่อไวรัสหลอดลมอักเสบติดต่อเมื่อไก่อายุ 1, 2, 3, 4, 5 และ 6 สัปดาห์ ผลการทดลองพบว่าไก่ที่ได้รับวัคซีนทุกกลุ่มมีน้ำหนักเฉลี่ยไม่แตกต่างกันอย่างมีนัยสำคัญทางสถิติ ($p>0.05$) ทั้งก่อนและหลังการได้รับเชื้อพิษทาบ แต่มีน้ำหนักดีกว่ากลุ่มควบคุม อย่างมีนัยสำคัญทางสถิติ ($p<0.05$) ภายหลังจากไก่ได้รับเชื้อพิษทาบ อัตราการตายในไก่กลุ่มที่ 3-5 ต่ำกว่ากลุ่มควบคุมผลบวก อย่างมีนัยสำคัญทางสถิติ ($p<0.05$) ระดับแอนติบอดีต่อเชื้อไวรัสหลอดลมอักเสบติดต่อของไก่กลุ่มที่ได้รับวัคซีนทุกกลุ่มสูงกว่าไก่กลุ่มควบคุมผลบวกอย่างมีนัยสำคัญทางสถิติ ($p<0.05$) ภายหลังจากได้รับเชื้อพิษ 2 สัปดาห์

คำสำคัญ: ไก่เนื้อ โรคหลอดลมอักเสบติดต่อชนิดที่ทำให้เกิดรอยโรคที่ไต วัคซีน

¹ภาควิชาอายุรศาสตร์ คณะสัตวแพทยศาสตร์ มหาวิทยาลัยขอนแก่น อ.เมือง จ.ขอนแก่น 40002

²ภาควิชาอายุรศาสตร์ คณะสัตวแพทยศาสตร์ จุฬาลงกรณ์มหาวิทยาลัย ปทุมวัน กรุงเทพฯ 10330

*ผู้รับผิดชอบบทความ Email: jiroj.s@chula.ac.th

Introduction

Infectious bronchitis (IB) caused by infectious bronchitis virus (IBV) is a common health problem in poultry that has a high economic impact especially in the chicken industry in most countries of the world. The IBV can damage the respiratory tract in chickens of all ages (Parson et al, 1992). The severity of the disease varies by age. In young chickens, symptoms are more severe and the mortality rate is higher when compared to adult chickens (Animas et al., 1994). Infected chickens show a decrease in growth rate and an increased in feed conversion ratio. The disease is a risk factor for secondary bacterial infections of the respiratory tract resulting in an even higher morbidity and mortality rate (Ziegler et al., 2002). The decrease in egg production can be up to 30% in infected layers (Gough et al., 1992). Nephropathogenic infectious bronchitis (NIB) strains cause lesions in the kidneys; for example, nephritis, enlarged kidneys, pale kidneys and accumulated urate in the ureter (Ziegler et al., 2002).

The occurrence of NIB has been reported in many countries. The mortality rate of infected chickens with NIB is 23-30% (Ziegler et al., 2002). In Thailand, NIB is an endemic disease that can be found all over the country. Upatoom et al. (1983) reported incidences in the north-east of Thailand in broilers aged 14-28 days with

1-15% mortality rate. Among other reports were, 35 incidences in the south of Thailand, 29 in broilers aged 12-44 days, 5 in layers aged 8-40 weeks and 1 in 3 months old native chickens. Respiratory symptoms along with enlarged kidneys were observed in 21 incidences and enlarged kidneys only were observed in 4 incidences (Antarasena et al., 1990).

Vaccination for the prevention of IB is widely practiced. However, NIB has been isolated in vaccinated chickens. The vaccine failure may be caused by the differences in the genotypes or serotypes of vaccine strains and field strains (Pensaert and Lambrechts, 1994). In some cases, improvements in protection might be achieved by the use of a different IB vaccination (Fabio et al., 2000). At present, many strains of vaccine are commercially available. It is important to periodically evaluate the cross-protective capabilities of vaccines versus field isolates, because the outcomes of these studies will provide valuable information on the practical use of existing vaccines and the potential need for new ones. The objective of this study was to evaluate the efficacy of vaccines using Ma5, H120 and a local strain produced by the Department of Livestock Development (DLD) against NIB isolated from chickens in Thailand.

Materials and Methods

Virus propagation and titration: The viral agent, isolate THA001 (accession number DQ449628), was isolated from an infected chicken with respiratory and renal lesions in central part of Thailand in 1998 and preserved in allantoic fluid at -70°C. The preserved agent was thawed and then propagated by inoculation in embryonated chicken eggs via the allantoic cavity. The eggs were incubated at 37°C for 72 hours before being stored at 4°C for 12-18 hours. Then the allantoic fluid was collected and frozen at -70°C for stock solution.

Virus titration: Determination of the virus concentration in the stock solution was done by the 10 fold serial dilution method. Six, 10 days old embryonated chicken eggs were inoculated in the allantoic cavity with 0.1 ml per egg of each tenfold serial dilution of the virus and kept at 37°C. Seven days after the inoculation, the embryos were examined for IBV lesions (stunting, curled toes or urates in the mesonephrons) (Ziegler et al., 2002). The control embryonated eggs have no those lesions at the same period. The embryo infectious dose 50% (EID₅₀/0.1ml) was calculated according to Reed and Muench (1938).

Experimental design: One hundred, 1 week old female broiler chickens were randomly allocated into 5 groups with 20 chickens each and housed in separate experimental rooms. Feed and water were supplied *ad lib*. An infectious bronchitis vaccine was administered to the chickens via eye drops. Three kinds of commercial vaccines including Ma5 (Intervet, Holland), H120 (Intervet, Holland) and a local strain (DLD, Thailand) were used for vaccination. The groups were treated with the following regime; no infection and no vaccination (group 1), infection and no vaccination (group 2), infection and vaccination with Ma5 strain (group 3), infection and vaccination with H120 strain (group 4), infection and vaccination with local strain produced by DLD (group 5). The guidelines and legislative regulations on the use of animals for scientific purposes of Chulalongkorn University, Bangkok Thailand were followed as is certified in permission no. 16/2548.

Challenge inoculation: Three weeks after the vaccination, the chickens in groups 2-5 were inoculated with 100 µl of IBV via eye drops. The virus concentration was approximately 10^{5.85} EID₅₀.

Clinical signs, mortality and body weight gains: Clinical signs and mortality were observed and recorded for 2 weeks after the challenge. Necropsy was done on the carcasses for gross pathologic lesions. The chickens were weighed before the vaccination, the day before the challenge and at the end of the experiment.

Detection of IBV antibody titers: Before the vaccination, blood samples were randomly collected from 10 chickens.

Then, blood samples were randomly collected from 10 chickens in each group every week until the sixth week. The serum samples were preserved at -20°C. IBV antibody titer was monitored using commercial Enzyme Linked Immunosorbent Assay (ELISA) test kit (BioChek, Holland).

Statistical Analysis: A comparison of body weight and antibody titer among the experimental groups was done using ANOVA and the Duncan's Multiple Range test. The mortality rate among the groups was compared by Chi-square test.

Results

Clinical signs and mortality rate: After the challenge inoculation, infected chickens showed signs of respiratory disorders; i.e. nasal and ocular discharge, coughing, sniffing, mouth breathing and respiratory distress. Clinical signs of the gastrointestinal system observed included watery diarrhea and contamination of urate in feces. The mortality rate was 35% in group 2, which was infected but was not vaccinated, and the mortality rate was 5, 0, and 5% in groups 3, 4, and 5, respectively (Table 1). The mortality rate of group 2 significantly differed from those of the other groups ($p < 0.05$). Necropsy revealed that all the carcasses contained lesion in the trachea and the kidneys. Mucus accumulated in the trachea, enlarged kidneys and an accumulation of urate in the ureter were observed in the necropsied chickens.

Body weight of chickens: The body weight of the chickens in each group did not significantly differ at 1 and 4 weeks old ($p > 0.05$). At 6 weeks old, 2 weeks after challenge inoculation, the average body weight of the chickens in group 2 was significantly less than the other groups ($p < 0.05$) but no significant difference to the average body weight was found among the other groups ($p > 0.05$) (Table 1).

IBV Antibody titers: At 2 weeks old, the average IBV antibody titer of all groups was not significantly different. At 3 weeks old, the chickens in group 4 had the highest average IBV antibody titer and it was significantly different from the others ($p < 0.05$). At 4 and 5 weeks old, the chickens in group 2 had the lowest average IBV antibody titer and it was significantly different from groups 3 and 4 ($p < 0.05$) but not significantly different from group 5 ($p > 0.05$). Interestingly, the average IBV antibody titer at 5 weeks old of all the vaccinated groups was distinctly elevated above the unvaccinated group (Figure 1). At the end of experiment (6 weeks old), the chickens in groups 3, 4 and 5 had significantly higher the average IBV antibody titers than the chickens in group 2 ($p < 0.05$). No chickens from group 1 (negative control)

Table 1 Body weight and mortality rate of the chickens in each group

Group	Vaccination	Body Weight (gram±SD)			Number of Death/Total (%)
		1 week old	4 weeks old	6 weeks old	
1	negative control	178.3±11.3 ^a	1223.0±67.4 ^a	2036.0±100.9 ^a	0/20(0) ^a
2	positive control	178.0±11.7 ^a	1226.0±80.4 ^a	1886.9±337.5 ^b	7/20(35) ^b
3	Ma5	178.0±11.8 ^a	1269.0±66.4 ^a	2052.6±164.6 ^a	1/20(5) ^a
4	H120	176.5±11.6 ^a	1262.5±70.7 ^a	2043.0±143.4 ^a	0/20(0) ^a
5	DLD	178.3±11.7 ^a	1268.5±84.3 ^a	2093.2±150.1 ^a	1/20(5) ^a

Different superscripts in the same column indicate significant difference ($p < 0.05$)

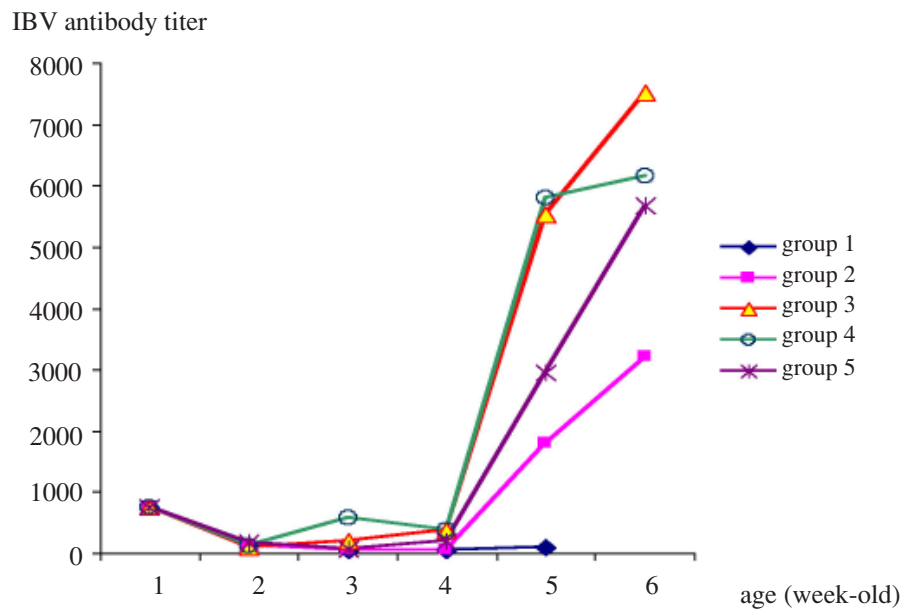


Figure 1 The average IBV antibody titers of the chickens in each group

were positive for IBV antibodies during the time of the experiment.

Discussion

The mortality rate of the chickens that were vaccinated (0-5%) was lower when compared to infected chickens that were not vaccinated (35%), indicated that the vaccines used in this study could induce cross protection against the field challenge strain that causes NIB. These results are consistent with other studies that show cross protection between different strains of vaccine. Darbyshire (1985) reported that the H120 strain vaccine was effective against the Australian T strain of IBV, which was able to cause renal lesions. The vaccine could reduce the amount of agent 30,000 times within 4 days of infection. Wang et al. (1996) evaluated the efficacy of the H120 strain vaccine by observing the movement of cilia in the trachea and renal lesions caused by 1171 and 1449 strains and found that only 1 in 10 chickens that had received the 1171 strain and none of the chickens

that had received the 1449 strain showed signs of infection. Albassam et al. (1986) showed that chickens that had received the H120 strain vaccine at 10 days old and were infected 4 weeks later with strains that caused renal lesions; Gray, Holte, Australian T and Italian, did not show tracheal lesions but 50-70% of the chickens showed renal lesions. This indicated partial protection of the vaccine across the strains. It has been known that the trachea is a primary site for the IBV to propagate. Live vaccines can reduce mortality in infected animals due to mucosal immunity induced by the virus. The mucosal immunity prohibits invasion and propagation of the virus in the tracheal mucosa. When the vaccine strain is different from the strain that causes infection, some infectious agents overcome the immune mechanism and invade the kidneys resulting in morbidity which is less severe (Pensaert and Lambrechts, 1994). Thompson et al. (1997) examined the mucosal immunity of infected chickens and found that 70% of the samples contained IgA, 52% and 56% of the samples contained IgG and IgM, respectively. Nakamura et al.

(1991) found IgM, IgA, and IgG in the trachea more often in chickens that were resistant to the disease compared to susceptible chickens. Live vaccines can also induce cellular immunity, which can prohibit virus attack as well. Pei et al. (2003) found that transfer of CD8+ T cell isolated during 3-6 weeks after infection caused by IBV to 6 days old chicks can protect the chicks from infection.

The average antibody titer of vaccinated chickens after the challenge was higher than those of unvaccinated chickens due to recognition of the virus by the immune system (Thompson et al., 1997). There were 11 sites (epitopes) of spike glycoprotein, which is located on the envelope of the infectious bronchitis virus, that are specific to antibodies. These epitopes are 7 type specific epitopes and 4 group specific epitopes (Parr and Collisson, 1993). The cross protection observed in this study may be caused by group specific epitopes that stimulate the immune response to the challenge virus. At 6 weeks old, body weight and mortality rate of vaccinated chickens, which received the challenge virus, and the negative control chickens were not different but they were significantly better than those of the positive control chickens. The results indicate the protective efficacy of all tested vaccines, namely Ma5, H120 and DLD against the local NIB strain.

Acknowledgements

This work was supported by a fund from Khon Kaen University, Thailand. We thank Asst. Prof. Dr. Khankate Kanistanon for her assistance in the manuscript preparation.

References

- Albassam, A.M., Winterfield, W.R. and Thacker, L.H. 1986. Comparison of the nephropathogenicity of four strains of infectious bronchitis virus. *Avian Dis.* 30(3): 468-476.
- Animas, B.S., Otsuki, K., Hanayama, M., Sanekata, T. and Tsubokura, M. 1994. Experimental infection with avian infectious bronchitis virus (Kagoshima-34 strain) in chicks at different ages. *J. Vet. Med. Sci.* 56(3): 443-447.
- Antarasena, C., Sahapong, S., Aowcharoen, B., Choe-ngern, N. and Kongkanunt, R. 1990. Avian infectious bronchitis in the Southern part of Thailand. *Songklanakarini J. Sci. Technol.* 12(3): 273-279.
- Darbyshire, J.H. 1985. A clearance test to assess protection in chickens vaccinated against avian infectious bronchitis virus. *Avian Path.* 14(4): 497-508.
- Fabrio, J.D., Rossini, L.I., Orbell, S.J., Paul, G., Huggins, M.B., Malo, A., Silva, B.G.M. and Cook, J.K.A. 2000. Characterization of infectious bronchitis viruses isolated from outbreaks of disease in commercial flocks in Brazil. *Avian Dis.* 44(3): 582-589.
- Gough, E.R., Randall, J.C., Dagless, M., Alexander, J.D., Cox, J.W. and Pearson, D. 1992. A new strain of infectious bronchitis virus infecting domestic fowl in Great Britain. *Vet. Rec.* 130(22): 493-494.
- Nakamura, K., Cook, A.K.J., Otsuki, K., Huggins, B.M. and Frazier, A.J. 1991. Comparative study of respiratory lesion in two chicken lines of different susceptibility infected with infectious bronchitis virus: histology, ultrastructure and immunohistochemistry. *Avian Path.* 20(2): 241-257.
- Parr, L.R. and Collisson, E. W. 1993. Epitopes on the spike protein of a nephropathogenic strain of infectious bronchitis virus. *Arch Virol.* 133(3-4): 369-383.
- Parsons, D., Ellis, M.M., Cavannagh, D. and Cook, A.K.J. 1992. Characterisation of an infectious bronchitis virus isolated from vaccinated broiler breeder flocks. *Vet. Rec.* 131(18): 408-411.
- Pei, J., Briles, W.E. and Collisson, E.W. 2003. Memory T cells protect chicks from acute infectious bronchitis virus infection. *Virol.* 306(2): 376-384.
- Pensaert, M. and Lambrechts, C. 1994. Vaccination of chickens against a Belgian nephropathogenic strain of infectious bronchitis virus B1648 using attenuated homologous and heterologous strains. *Avian Path.* 23(4): 631-641.
- Reed, L.R. and Muench, H. 1938. A simple method of estimating fifty percent endpoints. *Am. J. Hyg.* 27(3): 493-497.
- Thompson, G., Mohammed, H., Buaman, B. and Naqi, S. 1997. Systemic and local antibody responses to infectious bronchitis virus in chickens inoculated with infectious bursal diseases virus and control chickens. *Avian Dis.* 41(3): 519-527.
- Wang, C.H., Hsieh, M.C. and Chang, P.C. 1996. Isolation, pathogenicity, and H120 protection efficacy of infectious bronchitis viruses isolated in Taiwan. *Avian Dis.* 40(3): 620-625.
- Upatoom, N., Jirathanawat, V., Srihakim, S., Leesirikul, N., Chirawatanapong, W., Bunyahotra, R., Siriwan, P. and Likitdecharoj, B. 1983. Infectious bronchitis (nephritis-nephrosis) in broilers. *Thai. J. Vet. Med.* 13(1): 36-43.
- Ziegler, F.A., Ladman, S.B., Dunn, A.P., Schneider, A., Davison, S., Miller, G.P., Lu, H., Weinstock, D., Slem, M., Eckroade, J.R. and Gelb, J. 2002. Nephropathogenic infectious bronchitis in Pennsylvania chickens 1997-2000. *Avian Dis.* 46(4): 847-858.