

12-1-1984

Ataxic hemiparesis from intraventricular bleeding

Thiravat Hemachudha

Kammant Phanthumchinda

Follow this and additional works at: <https://digital.car.chula.ac.th/clmjournal>



Part of the [Medicine and Health Sciences Commons](#)

Recommended Citation

Hemachudha, Thiravat and Phanthumchinda, Kammant (1984) "Ataxic hemiparesis from intraventricular bleeding," *Chulalongkorn Medical Journal*: Vol. 28: Iss. 12, Article 7.

DOI: 10.58837/CHULA.CMJ.28.12.7

Available at: <https://digital.car.chula.ac.th/clmjournal/vol28/iss12/7>

This Case Report is brought to you for free and open access by the Chulalongkorn Journal Online (CUJO) at Chula Digital Collections. It has been accepted for inclusion in Chulalongkorn Medical Journal by an authorized editor of Chula Digital Collections. For more information, please contact ChulaDC@car.chula.ac.th.

Ataxic hemiparesis from intraventricular bleeding

Thiravat Hemachudha*

Kamman Phanthumchinda*

ธีระวัฒน์ เหมะจุธา, กัมมันต์ พันธุมจินดา. กลุ่มอาการ Ataxic hemiparesis จากเลือดออกในช่องโพรงสมอง. จุฬาลงกรณ์เวชสาร ธันวาคม ; 28 (12) : 1399-1402

รายงานผู้ป่วย 1 ราย มาด้วยอาการอ่อนแรงของแขนขาด้านขวา ร่วมกับมีอาการทาง Cerebellum ของด้านเดียวกัน จากการวิเคราะห์ด้วยเครื่องเอ็กซเรย์คอมพิวเตอร์พบว่า มีเลือดออกในช่องโพรงด้านซ้าย โดยไม่มีหลักฐานของการตกเลือดภายในเนื้อสมอง พยาธิสภาพดังกล่าวที่ร่วมไปกับกลุ่มอาการนี้ ยังไม่เคยมีผู้ใดรายงานมาก่อน จากการวิเคราะห์รายงานที่มีผู้เสนอเกี่ยวกับกลุ่มอาการนี้ มักจะเป็นเรื่องของ Lacunar Infarction เกือบทั้งหมด

* Department of Medicine, Faculty of Medicine, Chulalongkorn University.

Ataxic hemiparesis, as described by Miller Fisher in 1978⁽¹⁾, is one of the Lacunar syndromes characterized by weakness and cerebellar like ataxias of the same side affecting the leg more than the arm. This syndrome is believed to be due to lesions of either supratentorial or infratentorial structures.^(1,2,3,4) The pathologies are mostly vascular in nature although mass lesions have been reported.⁽⁶⁾

We recently studied a patient with this syndrome with CT evidence of ventricular bleeding, who made an excellent recovery.

Case report

A 56 years old hypertensive, right handed Thai male experienced a sudden onset of clumsiness in the right lower extremity which was at first not associated with weakness. There was numbness of the right leg at the onset which he described to be like something wrapped around his foot. As he walked to the physician's room, the right leg tended to "fall out in the wrong direction"; he also noted a mild weakness in the right arm and leg. Examination one hour later revealed a BP of 190/140 mmHg when he was given methyldopa 500 mgs and propranolol 20 mgs orally without any improvement in his neurological deficits. Instead, headache and dizziness developed and increased in severity. He was then referred to the Neurology Division, Chulalongkorn Hospital and arrived 1½ hours later.

Examination at this time revealed moderate obesity and a BP of 130/110 mmHg. The patient was alert and in normal mental status. The carotid pulses

were equal and bruits not heard. Abnormal neurological findings consisted of a mild weakness of the right side, the leg being more affected than the arm. Cranial nerve functions were intact. No nystagmus was observed.

There was definite dysmetria of the right upper and lower extremity which was mild in the arm and more severe in the leg. Rapid alternating movements were clumsy on the right. In the heel-knee test, the right thigh tended to fall laterally which could not be entirely explained by the very mild degree of weakness. Although numbness was a complaint at the onset of his illness, sensory function was normal for touch, pain, vibration and proprioception, as well as in the double simultaneous testing. Deep tendon reflexes on the right were decreased when compared to the left. Babinski responses and clonus were absent. Weakness disappeared but cerebellar signs were still present on the 3rd day of hospitalization. CT scan on that day revealed high density area with the mean attenuation value of 60 HU, in the left lateral ventricle which represented intraventricular bleeding. No evidence of intracerebral mass lesion was seen.

He was conservatively managed with mild antihypertensive agents and simple analgesics for his headache which gradually subsided over a few days. Neurological deficits were no longer detectable at the end of the second week.

Comment

The clinical features of ipsilateral cerebellar-like ataxia and weakness was initially recognized by Fisher and Cole⁽²⁾ who called it "Homolateral ataxia and

crural paresis". Similar findings were later reported by many authors as "Dysarthria-clumsy hand syndrome"⁽⁶⁾ and recently as "Ataxic hemiparesis".⁽¹⁾ The anatomical lesions responsible for the latter syndrome are in the posterior limb of the internal capsule and corona radiata contralateral to the symptomatic side^(2,4,7), and infarction is the usual etiology. Infratentorial pathologies however, may either be lacunes in the basis pontis at the level of the junction of the upper one-third and lower two-thirds of the opposite side⁽¹⁾, or a mass in the midbrain region.⁽⁵⁾

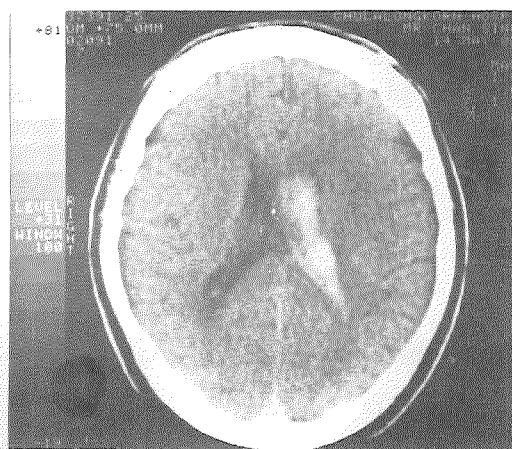
Ataxia resulting from supratentorial lesions is caused by the interruption of corticopontine fibers (Frontopontine, temporopontine, parieto and occipitopontine) that project firstly to the ipsilateral pontine nuclei by way of the internal capsule.⁽⁸⁾ Frontopontine tracts arise from the prefrontal cortex (areas 10, 9, 8, 45, 46) and occupy the anterior limb, while precentral (from areas 4

and 6) descend via the posterior limb of the internal capsule. Inaccurate and uncoordinated volitional movements could also result from lesions of the sensory association cortex.^(9,10,11,12) Cerebellar ataxia-like symptoms are due to the failure of corticocortical transmission of important information to the motor areas.

The etiology in our patient was from an intraventricular bleeding which had never been described in previous literature. We believe that the cerebellar-like dysmetria and weakness in this case could best be explained by a secondary pressure from or an ischemic effect of the bleeding, on the frontopontine fibers in the adjacent anterior limb of the internal capsule and rostral end of the posterior limb, which carries corticospinal tracts. A study of other cases of ventricular bleeding at our hospital did not reveal any sign of dysmetria or ataxic hemiparesis as presented above.

Acknowledgement :

The authors are indebted to Dr. Nittaya Suwanvela for her valuable suggestion on CT Scan.



CT Scan of the brain revealed bleeding into the left lateral ventricle without any evidence of intracerebral hematoma

References

1. Fisher CM. Ataxic hemiparesis : a pathologic study. Arch Neurol 1978 Mar ; 35 (3) : 126-128
2. Fisher CM, Cole M. Homolateral ataxia and crural paresis : a vascular syndrome. J Neurol Neurosurg Psychiatry 1965 Feb ; 28 (2) : 48-55
3. Perman GP, Racy A. Homolateral ataxia and crural paresis : case report. Neurology 1980 Sep ; 30 (9) : 1013-1015
4. Lage JJ, Lepore FE. Ataxic hemiparesis from lesions of the corona radiata. Arch Neurol 1983 Jul ; 40 (7) : 449-450
5. Bendheim PE, Berg BO. Ataxic hemiparesis from a midbrain mass. Ann Neurol 1981 Apr ; 9 (4) : 405-407
6. Fisher CM. A lacunar stroke : the dysarthria-clumsy hand syndrome. Neurology (Minneapolis) 1967 Jun ; 17 (6) : 614-617
7. Iraqui VJ, McCutchen CB. Capsular ataxic hemiparesis. Arch Neurol 1982 Aug ; 39 (8) : 528-529
8. Garcin R, The ataxias. In : Venken PJ, Bruyn GW, eds. Handbook of Clinical Neurology. Vol 1. Disturbances of Nervous Function. New York : Elsevier North Holland, 1969. 309-355
9. Haaxna R, Kuypers HGJM. Intrehemispheric cortical connexions and visual guidance of hand and finger movements in the rhesus monkey. Brain 1975 Jun ; 98 (2) : 239-260
10. Stein J. Effects of parietal lobe cooling on manipulative behavior in the conscious monkey. In : Goron G, ed. Active Touch. Oxford, England : Pergamon Press, 1978. 79-90
11. Jones EG, Powell TPS. An anatomical study of converging sensory pathways within the cerebral cortex of the monkey. Brain 1970 Dec ; 93 (4) : 793-820
12. Montgomery EB. Signs and symptoms from a cerebral lesion that suggest cerebellar dysfunction. Arch Neurol 1983 Jul ; 40 (7) : 422-423