

The Thai Journal of Veterinary Medicine

Volume 39
Issue 1 March, 2009

Article 6

3-1-2009

Ophthalmology Snapshot

Nalinee Tuntivanich

Follow this and additional works at: <https://digital.car.chula.ac.th/tjvm>



Part of the [Veterinary Medicine Commons](#)

Recommended Citation

Tuntivanich, Nalinee (2009) "Ophthalmology Snapshot," *The Thai Journal of Veterinary Medicine*: Vol. 39: Iss. 1, Article 6.

Available at: <https://digital.car.chula.ac.th/tjvm/vol39/iss1/6>

This Other is brought to you for free and open access by the Chulalongkorn Journal Online (CUJO) at Chula Digital Collections. It has been accepted for inclusion in The Thai Journal of Veterinary Medicine by an authorized editor of Chula Digital Collections. For more information, please contact ChulaDC@car.chula.ac.th.

Ophthalmology Snapshot

Nalinee Tuntivanich

History

A 2 year-old, female Golden retriever has had opacity on both corneas for several weeks. The dog was referred to the small animal teaching hospital, Faculty of Veterinary Science, Chulalongkorn University from private animal hospital after a one month-period of non-responding treatment with topical Terramycin ointment.

From ophthalmic examination, the opacity that was oval with edge of the lesion well demarcated was nearly symmetric between both eyes. Fluorescein staining test revealed intact corneal epithelium. Neither ocular pain nor signs of keratitis was associated.

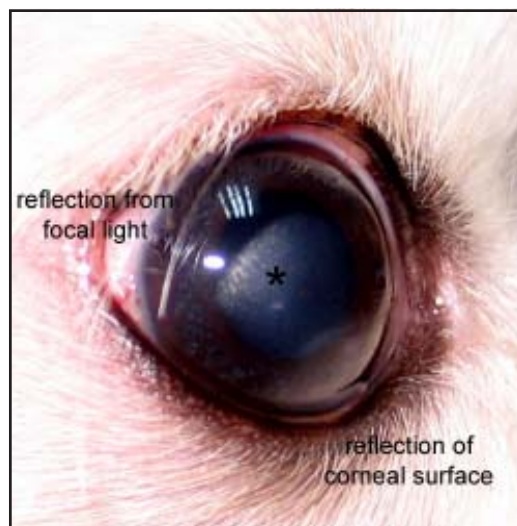


Figure 1 Nebular-type oval corneal opacity on the right eye asterisk in Golden retriever. The lesion located at the paracentral cornea has variation in density.

Questions

1. What is this corneal disorder?
2. Give reasons to support your answer to question 1.

(For better quality, figures can be viewed in the TJVM website.)

Please turn to the next page for answers

Answers

1. Corneal dystrophy, corneal lipid dystrophy, corneal stromal dystrophy

2. Bilateral and symmetrical lesion was silver, metallic appearance. Cornea was not accompanied by inflammation according to the fact that no sign of keratitis was involved. Golden retriever is one the dog breeds reported having corneal dystrophy.

Comments

Corneal stromal dystrophy is an inherited corneal abnormality, in which mode of inheritance has not been identified in Golden retriever. Other breeds such as American/English cocker spaniel, Beagle, Collie, Bichon fries, German shepherd, etc are also affected by this disorder. The whitish metallic, crystalline opacity on the cornea well shown by slit-lamp examination was commonly cholesterol resulting from disorder of lipid metabolism in the cornea. Progression varies with breeds. In Golden retriever, lipid accumulation is usually in the subepithelium

and/or the anterior stroma. Even though the disorder can progress in this breed but it was rare to impair vision. As long as there is no ocular discomfort or visual interference, treatment is unnecessary. To rule out if this corneal disorder is related to systemic disease such as thyroid or adrenal abnormalities, serum chemistry panel checked for cholesterol, lipoprotein, triglyceride, calcium or phosphorus level may be helpful.

References

- Whitley, R.D. and Gilger, B.C. 1999. Diseases of the canine cornea and sclera. In: *Veterinary Ophthalmology*. 3rd ed. K.N. Gelatt Lippincott Williams & Wilkins, Philadelphia. 655-662.
2. Laus, J.S., dos Santos, C., Talieri, I.C., Oria, A.P. and Bechara, G.H. 2002. Combined corneal lipid and calcium degeneration in a dog with hyperadrenocorticism: a case report. *Vet Ophthalmol*. 5(1): 61-64.