

The Thai Journal of Veterinary Medicine

Volume 38
Issue 4 December, 2008

Article 7

12-1-2008

Ophthalmology Snapshot

Nalinee Tuntivanich

Follow this and additional works at: <https://digital.car.chula.ac.th/tjvm>



Part of the [Veterinary Medicine Commons](#)

Recommended Citation

Tuntivanich, Nalinee (2008) "Ophthalmology Snapshot," *The Thai Journal of Veterinary Medicine*: Vol. 38: Iss. 4, Article 7.

Available at: <https://digital.car.chula.ac.th/tjvm/vol38/iss4/7>

This Other is brought to you for free and open access by the Chulalongkorn Journal Online (CUJO) at Chula Digital Collections. It has been accepted for inclusion in The Thai Journal of Veterinary Medicine by an authorized editor of Chula Digital Collections. For more information, please contact ChulaDC@car.chula.ac.th.

Ophthalmology Snapshot

Nalinee Tuntivanich

History

A 1-yr-old male Shih-Tzu was brought in to the ophthalmology clinic, small animal teaching hospital, Chulalongkorn University with a complaint of persistent cloudy cornea. This dog was in the past 2 weeks seen by a veterinarian. Topical antibiotic was prescribed but the cloudy cornea still remained.

Ophthalmic examination revealed corneal opacity, which was negative to fluorescein staining test. Slight inflammation of the bulbar conjunctiva was observed, together with mild degree of chemosis on the palpebral conjunctiva.

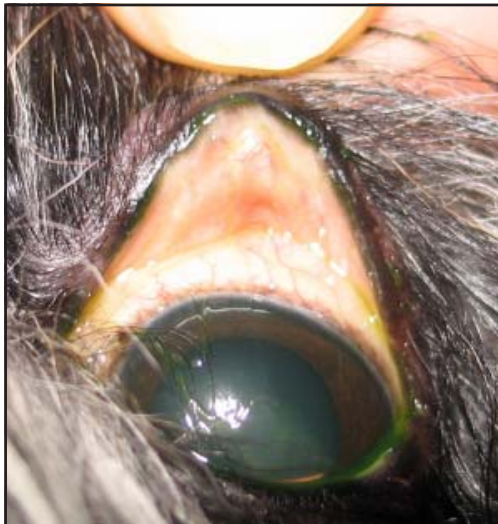


Figure 1. Ocular adnexa of a Shin-Tzu

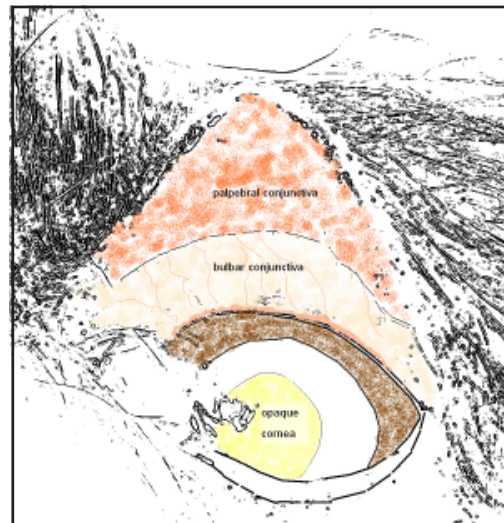


Figure 2. Schematic diagram of figure 1.

Questions

1. What may cause persistent corneal opacity in this dog?
2. What is the treatment of the answer to question 1?

(For better quality, figures can be viewed in the TJVM website.)

Please turn to the next page for answers

Answers

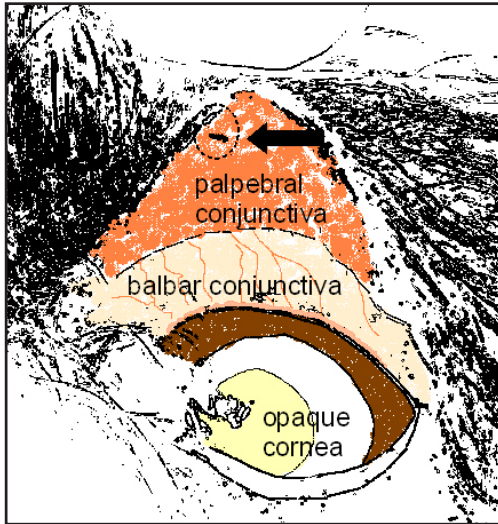


Figure 3. Schematic diagram of figure 1 demonstrating cilia (arrow) embedded in the upper palpebral conjunctiva.

1. Ectopic cilia or atypical distichia.

2. The condition can be resolved by surgery to excise of hair and follicle or cryoepilation to freeze hair follicle prior to hair removal. If unerupted cilia can be seen subconjunctivally, it may be left untreated unless it erupts. Owners should understand that new abnormal hairs can grow from new site after surgery.

Comments

Ectopic cilia are abnormal hairs that may emerge singly or in clumps from meibomian gland through the palpebral conjunctiva. This condition is common in young adult Shih Tzu however other dog breeds can also be seen during the same age. Clinical signs of ocular discomfort such as blepharospasm and lacrimation may

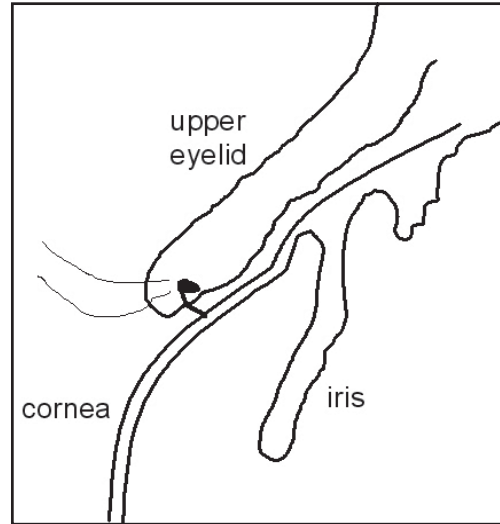


Figure 4. Ectopic cilium that impinges directly to the cornea causing constant irritation.

be noticed before the emergence of the cilia. If the cilia erupt through the conjunctiva, they usually impinge directly on to the cornea causing intense pain. When this occurs, corneal ulcer is usually present. Because the cilia are very small, they are often misdiagnosed. Careful ophthalmic examination under magnification is therefore necessary.

References

- Barnett, K.C. and Crispin, S.M. 1998. Cornea. In: Feline Ophthalmology. An Atlas and Text. W.B. Saunders, London. 83-103
- Bedford, P.G. 1999. Diseases and surgery of the canine eyelids. In: Veterinary Ophthalmology. 3rd ed. by KN Gelatt (ed). Lippincott Williams & Wilkins, Philadelphia. 555-557