

# The Thai Journal of Veterinary Medicine

---

Volume 38  
Issue 4 December, 2008

Article 6

---

12-1-2008

## ECG Quiz

Chollada Buranakarl

Kris Angkanaporn

Winai Chansaisakorn

Follow this and additional works at: <https://digital.car.chula.ac.th/tjvm>



Part of the [Veterinary Medicine Commons](#)

---

### Recommended Citation

Buranakarl, Chollada; Angkanaporn, Kris; and Chansaisakorn, Winai (2008) "ECG Quiz," *The Thai Journal of Veterinary Medicine*: Vol. 38: Iss. 4, Article 6.

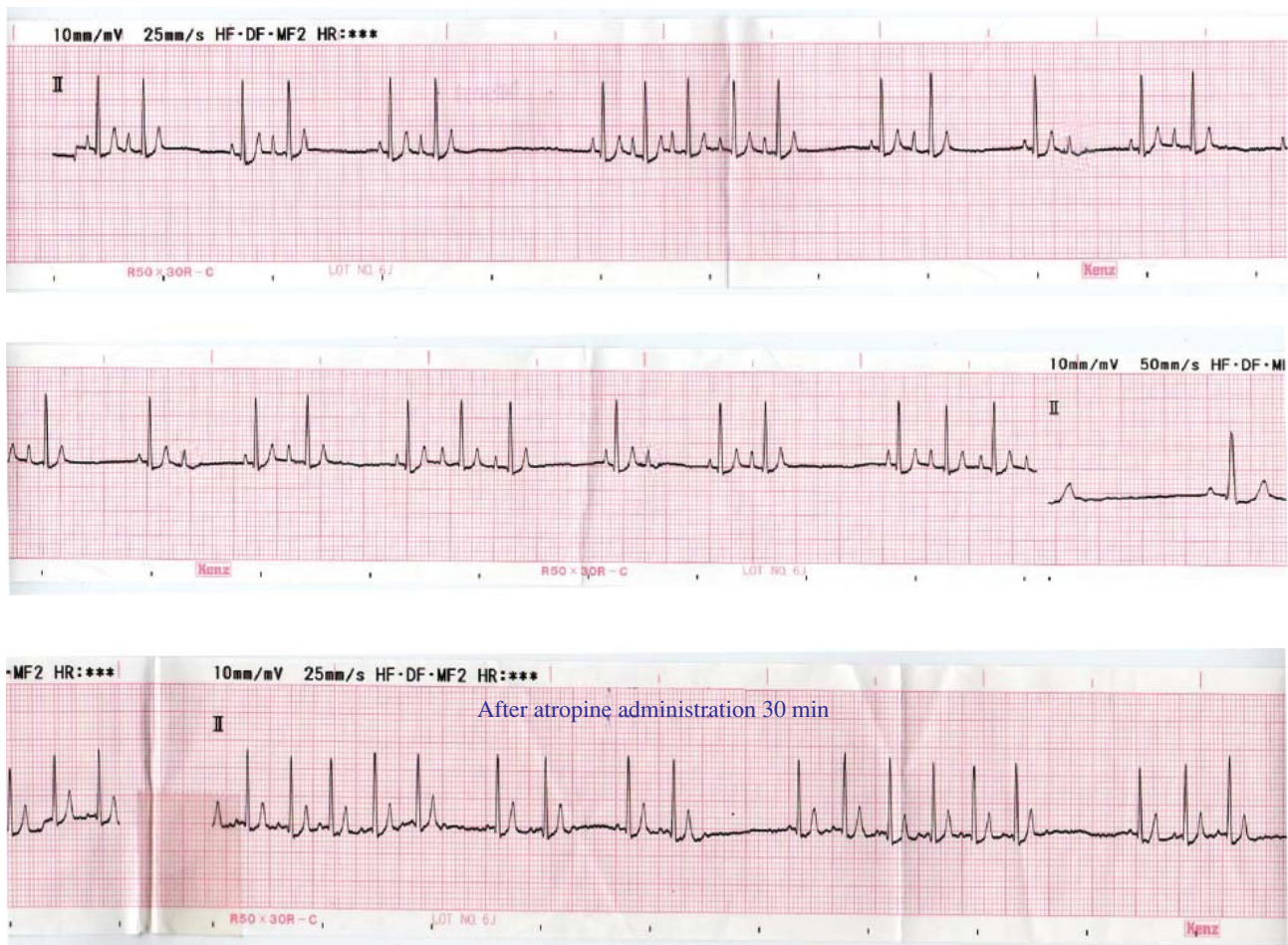
DOI: <https://doi.org/10.56808/2985-1130.2145>

Available at: <https://digital.car.chula.ac.th/tjvm/vol38/iss4/6>

This Other is brought to you for free and open access by the Chulalongkorn Journal Online (CUJO) at Chula Digital Collections. It has been accepted for inclusion in The Thai Journal of Veterinary Medicine by an authorized editor of Chula Digital Collections. For more information, please contact [ChulaDC@car.chula.ac.th](mailto:ChulaDC@car.chula.ac.th).

## ECG Quiz

Chollada Buranakarl<sup>1\*</sup> Kris Angkanaporn<sup>1</sup> Winai Chansaisakorn<sup>2</sup>



These lead II ECG strips were recorded from a 5 years old, female, spayed Shih Tzu that was referred to the Chulalongkorn University Small Animal Hospital with panting. Physical examination revealed pink mucous membrane, polyurea, polydipsia with normal appetite. Auscultation showed normal lung sound and

arrhythmic heart sound. Thoracic radiograph revealed left heart enlargement (VHS=10.2) and mild interstitial lung pattern. All hematological and serum chemistry profiles were within normal limits.

Please answer before turning to the next page.

---

<sup>1</sup>Department of Physiology, <sup>2</sup>Small Animal Hospital, Faculty of Veterinary Science, Chulalongkorn University

\*Corresponding author

## Interpretation

### Sinus arrhythmia with sinus pause and periodic second degree atrioventricular block

The heart rate was 90 beats per minute. The arrhythmic heart sound is corresponded to the ECG recording which shows some periods of sinoatrial (SA) pause. The pause may not be due to respiratory origin since the patterns of heart rate fluctuation do not decrease or increase progressively like we have seen in respiratory sinus arrhythmia and the periods of sinus pause are random. When heart beat stops, there are no P waves or QRS complexes and the intervals between beats are integers the normal P-P intervals. There are two types of SA pause. If the SA node just stops discharging,

the term “sinus arrest” is defined. However, if the sinus impulse is generated but does not get through the conduction path between sinus and right atrium, the term “sinus block” is used. Please notice that there is no escape beat after the period of SA pause.

There are some P waves without the following QRS complexes (circle in tracing I and II). Thus, the periodic second degree AV block is also found. The presence of SA pause with coexisting AV block in this case suggests that the aberrant vagal discharge may be responsible. After atropine administration, the non conducted P wave disappears and the period of sinus pause is shortened. Since the heart rate before giving atropine is within normal limit and no clinical signs occur, therefore, no medication is needed in this case.

