

9-1-2008

Ultrasound Diagnosis

Phiwipha Kamonrat

Follow this and additional works at: <https://digital.car.chula.ac.th/tjvm>



Part of the [Veterinary Medicine Commons](#)

Recommended Citation

Kamonrat, Phiwipha (2008) "Ultrasound Diagnosis," *The Thai Journal of Veterinary Medicine*: Vol. 38: Iss. 3, Article 10.

Available at: <https://digital.car.chula.ac.th/tjvm/vol38/iss3/10>

This Other is brought to you for free and open access by the Chulalongkorn Journal Online (CUJO) at Chula Digital Collections. It has been accepted for inclusion in The Thai Journal of Veterinary Medicine by an authorized editor of Chula Digital Collections. For more information, please contact ChulaDC@car.chula.ac.th.

Ultrasound Diagnosis

Phiwipha Kamonrat

History

A seven-year-old, female, Poodle dog was referred to the Chulalongkorn University, Small Animal, Veterinary Teaching Hospital for further investigation of a liver problem. This dog presented with clinical signs of anorexia, weakness, weight loss and vomiting for ten days. Physical examination revealed icterus mucous membranes and a slightly tensed abdomen. Abnormal haematological profiles included a leukocytosis, with a regenerative left shift (2.7×10^4 white blood cells/ μl , 84% neutrophils, 6% band cells, 8% lymphocytes, 2% monocyte) and a marked anemia (2.06×10^6 red blood cells/ μl , 5 g/dl hemoglobin, 19% hematocrit) with a blood morphology of anisocytosis. Blood parasite was not found. Elevated serum alanine aminotransferase (153 units) and alkaline phosphatase (6,350 units) activities with normal levels of blood urea nitrogen (10 mg%) and creatinine (0.2 mg%) were identified on the serum biochemical analyses. The hepatobiliary system was ultrasonographically examined to rule out extrahepatic obstruction in this icteric dog.

Ultrasonographic Findings

An ultrasonographic examination of the hepatobiliary system was performed using a real-time scanner with an 8 MHz, wide band microconvex, transducer. The echogenicity relationship of liver, spleen and kidney parenchyma were within a normal limits. The gall bladder was slightly distended with small amount of anechoic bile. The gall bladder wall was slightly thickened and hyperechoic. There was an about 2 cm irregular hyperechoic structure, with a distinct distal acoustic shadowing, in the dorsal portion of the gall bladder, when scanned the dog in dorsal recumbency (Figures 1A and 2A). This hyperechoic structure consisted of numerous, echogenic, sand-like materials, 1-2 mm in diameter, as demonstrated when repositioning the dog on its side (Figures 1B and 2B). These materials did not suspend after using gentle transducer agitation on the ventral abdomen, they gravitated to the dependent portion of the gall bladder immediately. Multiple views of scanning demonstrated mobility of these materials with distal acoustic shadowing. A mild pain was detected in the gall bladder region during scanning. Neither abnormalities of hepatic parenchyma nor dilation of the biliary tract related to complete common hepatic duct obstruction was observed.

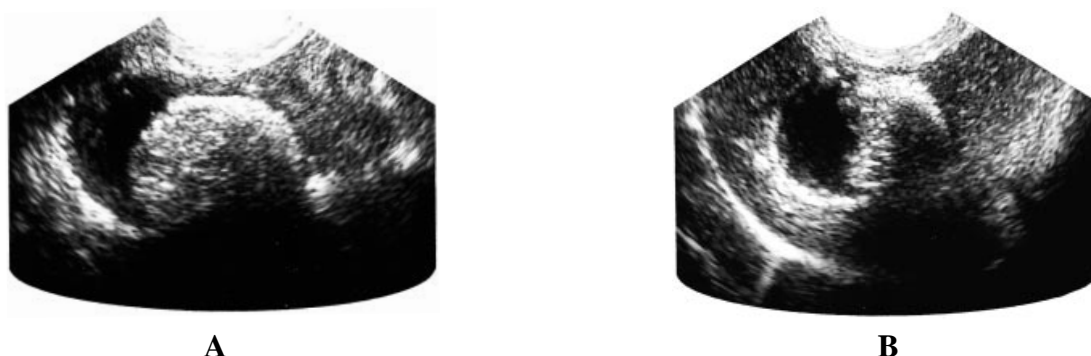


Figure 1 Transhepatic ultrasonograms of a seven-year-old, female, Poodle dog. The cholelith appeared as a large, discrete, irregular, hyperechoic material, with a distal acoustic shadowing, in the dorsal portion of the gall bladder, when the dog in dorsal recumbency (A). It consisted of numerous, small, hyperechoic particles, which gravitate to the dependent portion of the gall bladder immediately after repositioning the dog on its left side (B). Acoustic shadowing was evident distal to choleliths.

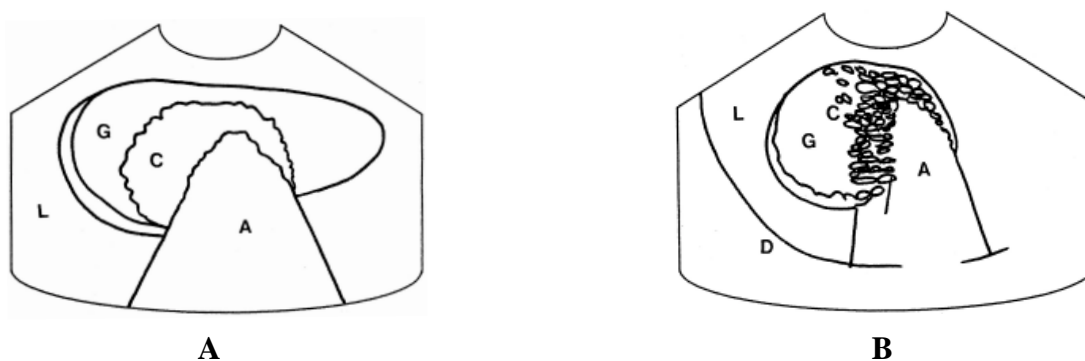


Figure 2 Schematics of the relative positions of the structures scanned in Figure 1. L - liver, G - gall bladder, C - cholelith, A - acoustic shadowing, D - diaphragm.

Diagnosis

Ultrasonographic diagnosis—Cholecystolithiasis.

Comments

Cholecystolithiasis may be seen as an incidental finding during ultrasonography in many animals. They may be large and well-defined or may consist of a sand- or sludge-like material. They will change their position within the gall bladder when changes in patient position. Observation of acoustic shadowing which evident distal to choleliths is a main criteria for ultrasonographic differentiating them from other space-occupying masses inside the gall bladder. This acoustic shadow is more distinct in the larger cholelith containing higher calcium content. Scanning the cholelith with a high frequency transducer will maximize this shadowing. However, not all kinds of choleliths in dogs create an acoustic shadow (Jensen et al., 1994). Therefore, the ultrasonographic finding of an intraluminal mass with the absence of distal acoustic shadowing in the gall bladder should not rule out the possibility of cholecystolithiasis in a dog.

On occasion, sediments shadow and choleliths may be suspected. The cholelith can be distinguished from shadowing sediments by repositioning the animal

or rapid agitating the gall bladder with back and forth transducer pressure. Sediments will suspend easily, but not choleliths which will gravitate immediately and always remain in the dependent portion of the gall bladder. Choleliths can be differentiated from shadowing intraluminal gas which rises to the nondependent position.

Thickening in the gall bladder wall is a nonspecific finding sometimes seen with acute or chronic hepatitis, cholecystitis or cholangiohepatitis. Differential diagnosis of shadowing lesions within the liver must include fibrosis, dystrophic calcification, foreign bodies and gas (Nyland et al., 2002). In this dog, the cholecystolithiasis was confirmed with abdominal radiographs as radiopaque sand calculi

References

- Jensen A.I., Koch J. and Snekvik K. 1994. Unusual ultrasonographic presentation of cholecystolithiasis in a dog. *J. Small Anim. Pract.* 35 (8) :420-422.
- Nyland T.G., Mattoon J.S., Herrgesell E.J. and Wisner E.R. 2002. Liver. In: *Small Animal Diagnostic Ultrasound*. 2nd ed. T.G. Nyland and J.S. Mattoon (eds.). Philadelphia: W.H. Saunders Company. 93-127.