

The Thai Journal of Veterinary Medicine

Volume 38
Issue 3 September, 2008

Article 9

9-1-2008

Ophthalmology Snapshot

Nalinee Tuntivanich

Follow this and additional works at: <https://digital.car.chula.ac.th/tjvm>



Part of the [Veterinary Medicine Commons](#)

Recommended Citation

Tuntivanich, Nalinee (2008) "Ophthalmology Snapshot," *The Thai Journal of Veterinary Medicine*: Vol. 38: Iss. 3, Article 9.

Available at: <https://digital.car.chula.ac.th/tjvm/vol38/iss3/9>

This Other is brought to you for free and open access by the Chulalongkorn Journal Online (CUJO) at Chula Digital Collections. It has been accepted for inclusion in The Thai Journal of Veterinary Medicine by an authorized editor of Chula Digital Collections. For more information, please contact ChulaDC@car.chula.ac.th.

Ophthalmology Snapshot

Nalinee Tuntivanich

History

An adult, male, stray cat was referred from a private clinic to the Ophthalmology Clinic, Small Animal Teaching Hospital, Faculty of Veterinary Science, Chulalongkorn University. From the referral note, the cat had a mass approximately 6-7 mm in diameter on the right cornea, which did not respond to a 3-day treatment

of systemic and topical antibiotics. This cat will hereafter be taken care of by a woman who found him.

Ophthalmic examination revealed negative menace response of the right eye. Cornea was severely edematous with a presence of a brown tissue-like mass at the paracentral area. The conjunctiva was reddened and swelling. The cat showed sign of photophobia and blepharospasm.

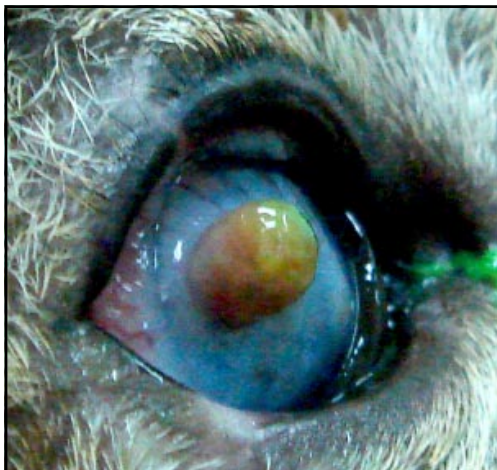

Figure 1. Oblique view of the cat's cornea, revealing a large tissue-like mass.

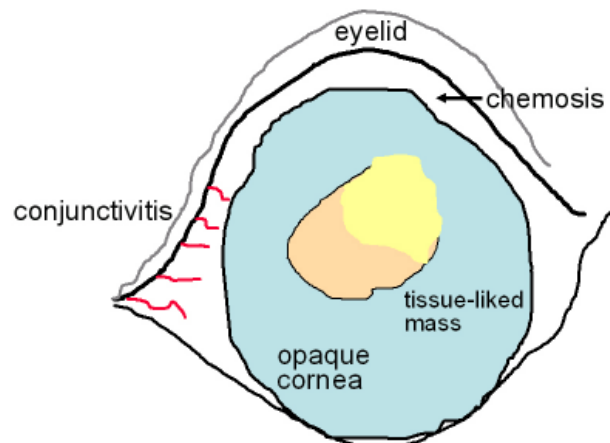


Figure 2. Schematic diagram of figure 1.

Questions

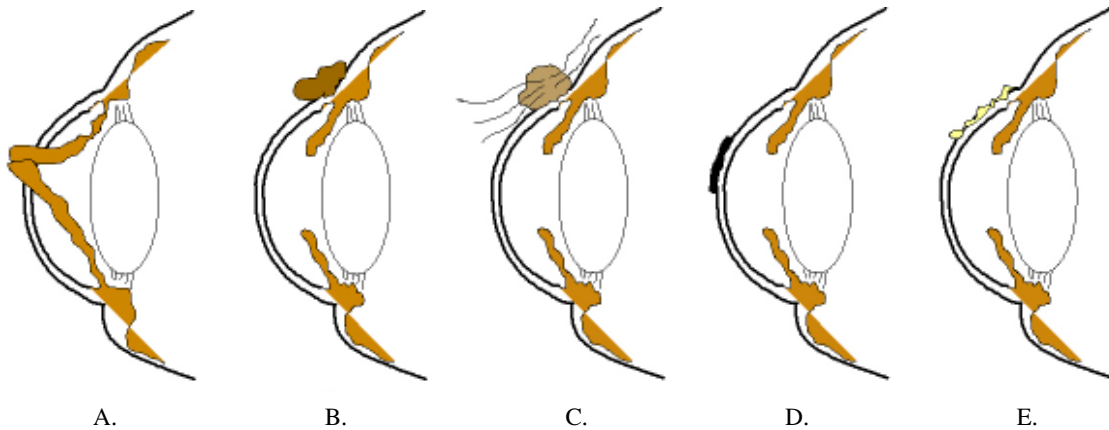
1. What are your differential diagnoses? Give reasons to support your answers
2. What is your tentative diagnosis? Give reasons to support your answer

(For better quality, figures can be viewed in the TJVM website.)

Please turn to the next page for answers

Answers

1. Differential diagnosis: anterior staphyloma, corneal neoplasm, dermoid growth, corneal sequestration and proliferative keratoconjunctivitis



1A. Anterior staphyloma is a protrusion of the anterior uvea (frequently, the iris) through ruptured cornea. Location of the prolapsed iris is various, depending on area of corneal perforation. Corneal inflammation is usually intense.

1B. Corneal neoplasm is very rare in cat. Corneoscleral region is more common as an origin of the primary neoplasm. Corneal melanocytoma is biologically located in the limbal area. The tumor is normally black or dark brown because it arises from melanocytes.

1C. Corneal dermoid growth is usually localized on the temporal region of the cornea. The mass comprises of skin structure therefore it is dark in color. Irritating hairs on the mass can cause chronic inflammation on the surrounding area.

1D. Corneal sequestration is unique in cat. Classic clinical sign is a black plaque of necrotic cells located at the central or paracentral area of the cornea. The lesion is often accompanied by corneal vascularization, edema and ulcer around the plaque.

1E. Proliferative keratoconjunctivitis is commonly found on the dorsolateral or ventrolateral quadrant of the cornea. It appears as a creamy white plaque-like material on the corneal superficial layer. Corneal vascularization as well as other signs of keratitis is not intense.

2. Tentative diagnosis: anterior staphyloma. Size, shape and color are more prone to be a mass, rather than a plaque. Based on location and appearance, dermoid growth is improbable. Edema of an entire cornea, conjunctivitis and signs of ocular pain indicate severe inflammation of the cornea and the adjacent ocular structures. Anterior uveitis is very likely to incorporate with ruptured cornea therefore vision can possibly be impaired. To facilitate the diagnosis, the position of the iris may be able to identify with an oblique examination of the cornea with a light source that has high-intensity round beam or a slit beam.

References

- Barnett KC and Crispin SM, 1998. Cornea. In: *Feline Ophthalmology. An Atlas and Text*. W.B. Saunders, London. 83-103
- Maggs, DJ, 2008. Cornea and sclera. In: *Slatter's fundamentals of veterinary ophthalmology*. 4th Ed. (Maggs, DJ, Miller PE, and Ofri R) Saunders, China. 175-202