

12-1-2007

What is Your Diagnosis?

Pranee Tuntivanich

Suwicha Chuthatep

Follow this and additional works at: <https://digital.car.chula.ac.th/tjvm>



Part of the [Veterinary Medicine Commons](#)

Recommended Citation

Tuntivanich, Pranee and Chuthatep, Suwicha (2007) "What is Your Diagnosis?," *The Thai Journal of Veterinary Medicine*: Vol. 37: Iss. 4, Article 8.

Available at: <https://digital.car.chula.ac.th/tjvm/vol37/iss4/8>

This Other is brought to you for free and open access by the Chulalongkorn Journal Online (CUJO) at Chula Digital Collections. It has been accepted for inclusion in The Thai Journal of Veterinary Medicine by an authorized editor of Chula Digital Collections. For more information, please contact ChulaDC@car.chula.ac.th.

What is Your Diagnosis

Pranee Tuntivanich Suwicha Chuthatep

Signalment

2-year-old male mixed breed dog.

History

The dog had been presented with a urinary incontinence for a year. Pollakiuria and hematuria were observed by the owner during the past 2 weeks.

Clinical Examination

Abdominal clamp was noticed during a palpation on the caudal abdominal area. Urine was obtained via cystocentesis for urinalysis with results indicating a pH

of 8.0 and proteinuria. Numbers of bacteria were also identified on microscopic examination of the urine sediment.

Radiographic Examination

Ventrodorsal and lateral abdominal radiographs were taken to assess the lower urinary tract abnormalities. Both negative-contrast and double-contrast cystograms were performed to evaluate chronic inflammation of the urinary bladder (UB) and mural abnormality of the UB wall respectively.

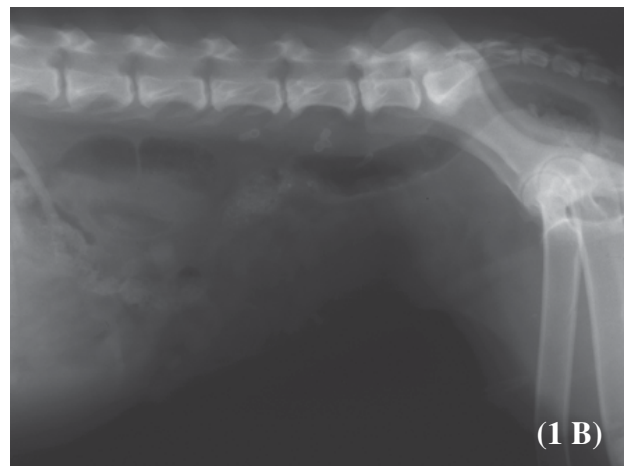
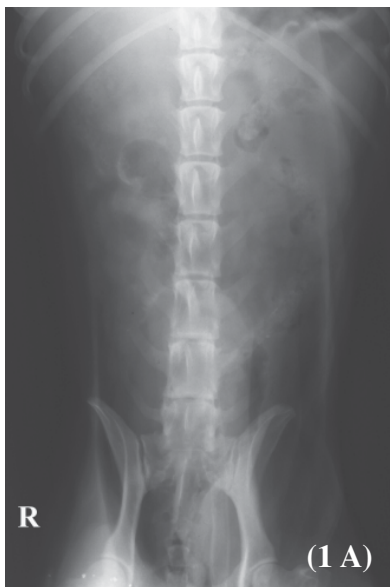
Figure 1A. Ventrodorsal abdominal radiograph

1B. Lateral abdominal radiograph

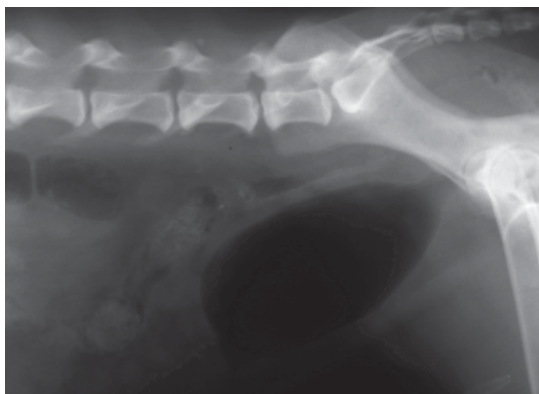

Figure 2. Negative-contrast cystograph

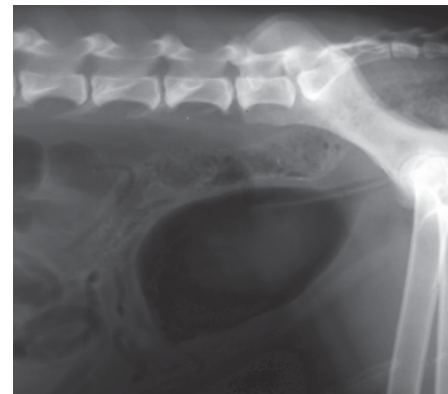

Figure 3. Double-contrast cystograph

Give your diagnosis and turn to the next page.

Radiographic findings

Ventrodorsal and lateral radiograph (Fig. 1A, B) showed a large UB silhouette with slight cranial displacement. There was no evidence of radiopacity indicating cystic calculi. Negative-contrast cystograph (Fig. 2) showed an increased UB wall thickness and

inadequate UB distension on the cranioventral aspect of the UB. A small diverticulum (small nipple-like protrusion) filled with small amount of positive contrast medium was obviously seen on the cranioventral aspect of the UB in the double-contrast cystograph (Fig. 3, 4).

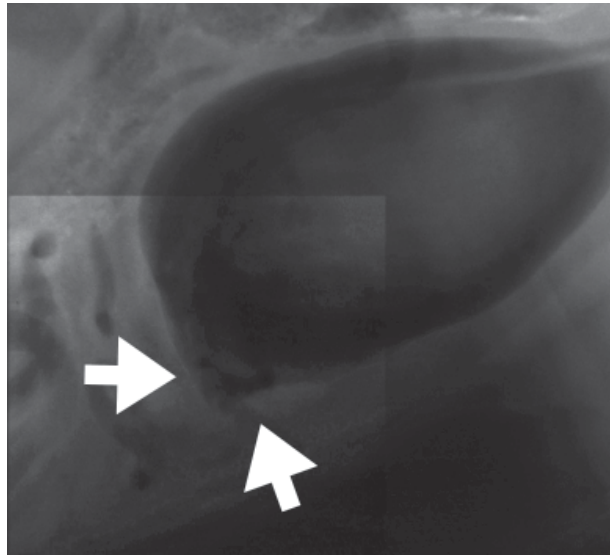


Figure 4. A small diverticulum in the cranioventral aspect of the UB (white arrows)

Radiographic diagnosis

Urachal diverticulum, chronic cystitis

Discussion

In the survey radiograph, UB may be evaluated by the presence of the position, shape, size and opacity which is inadequate in the diagnosis of UB abnormalities. Then, contrast cystography is often performed to provide more valuable diagnosis of UB disease.

Urachal diverticulum is a disease that appears as a small focal pouching at the apex of the UB wall. The adjacent UB wall is thickened. Mucosal change and intramural thickening of the UB wall are usually present in the radiograph. The dog may not show clinical signs of urinary tract disease but the dog may be predisposed to infection of the urinary tract by retained urine in the diverticulum. Urachal diverticulum can be effectively identified with positive-contrast cystography because of the presence of the residual contrast medium in the

diverticulum.

In cystography, injection of 2 to 5 ml of 2% lidocaine without epinephrine into the UB before cystography should be performed to avoid pain and spasm. In order to assess lesions of the UB wall and intraluminal filling defects, double-contrast cystography can be performed by injecting a small volume of positive-contrast medium (0.5-1ml for a cat, 1-3ml for a dog weighing less than 25lb, and 3-6ml for a dog weighing more than 25lb) into an empty UB. UB distention with negative-contrast medium is then followed.

References

- Park R.D. and Wrigley R.H. 2007. The urinary bladder. In: Textbook of veterinary diagnostic radiology. Thrall, D.E. 2002. 5thed. Saunders Elsevier. Missouri. 724-788.