

# The Thai Journal of Veterinary Medicine

---

Volume 37  
Issue 4 December, 2007

Article 6

---

12-1-2007

## Ophthalmology Snapshot

Nalinee Tuntivanich

Follow this and additional works at: <https://digital.car.chula.ac.th/tjvm>



Part of the [Veterinary Medicine Commons](#)

---

### Recommended Citation

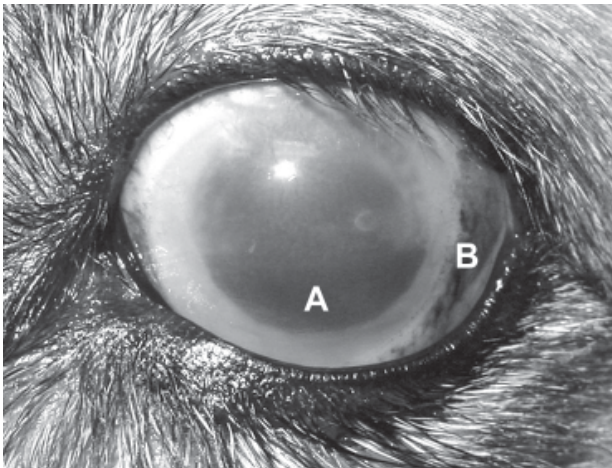
Tuntivanich, Nalinee (2007) "Ophthalmology Snapshot," *The Thai Journal of Veterinary Medicine*: Vol. 37: Iss. 4, Article 6.

Available at: <https://digital.car.chula.ac.th/tjvm/vol37/iss4/6>

This Other is brought to you for free and open access by the Chulalongkorn Journal Online (CUJO) at Chula Digital Collections. It has been accepted for inclusion in The Thai Journal of Veterinary Medicine by an authorized editor of Chula Digital Collections. For more information, please contact [ChulaDC@car.chula.ac.th](mailto:ChulaDC@car.chula.ac.th).

## Ophthalmology Snapshot

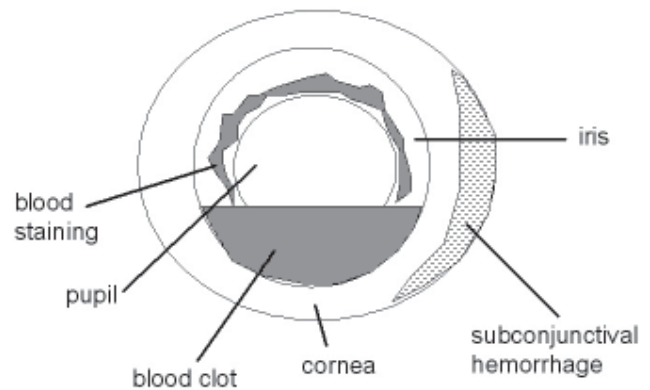
Nalinee Tuntivanich



**Figure 1.** Front view of the left eye.

Note: A = blood in the anterior chamber

Note: B = subconjunctival hemorrhage



**Figure 2.** Schematic diagram of ocular structures and abnormal signs corresponding to figure 1.

### History

A 5 year-old male mixed Terrier had a fight with a Thai dog that lives in the same household. The following day, the owner noticed a small bleeding from a bite wound on the forehead above the left eye of the mixed terrier. The dog was brought to the local veterinarian for wound management.

During a thorough examination, the veterinarian found a pool of blood in the left anterior chamber (Figure 1; A) approximately one third of the volume of the chamber as well as blood staining on the anterior pupillary iris. Subconjunctival hemorrhage was noticed temporally (Figure 1; B).

### Questions

1. What is the terminology of this abnormality (blood in the anterior chamber)?
2. How can you treat this abnormality?

Please turn to the next page for answers .....

## Answers

1. Hyphema or traumatic hyphema

2. Mild degree of hyphema (grade I: level of blood less than 1/3 of the height of the anterior chamber) can actually be resorbed over a period of days to weeks depending on the amount of blood present. Additional medical treatment facilitates blood resorption and reduces degree of iridocyclitis. Analgesic and non-steroidal anti-inflammatory drugs can be given to the dog with a serious caution of anti-platelet effect that can worsen the hyphema. Pupil is dilated with cycloplegic drug to help enhancing a resorption of blood. Tissue plasminogen activator can also be considered particularly for grade III and grade IV hyphema at which blood level covers 3/4 of the height of the chamber and an entire space of the chamber, respectively, to dissolve fibrin formation. Remained hyphema can cause an increase in intraocular pressure leading to glaucoma therefore anti-glaucoma medication should subsequently be considered. It is very important that the dog's activity is restricted to minimize the possibility of stimulating the recurrent or secondary hemorrhage.

Dogs with severe non-clotted hyphema, a consideration of anterior chamber paracentesis or irrigation and aspiration technique may help to remove blood elements and facilitate aqueous drainage. With prolonged severe clotted hyphema not responding to medical treatment, irrigation with trabeculectomy to

remove blood clot may be performed to reduce a risk of filtration angle blockage. However, a good understanding of complications that may occur following intraocular surgery is required.

## Comments

When hyphema is noticed, a detailed history and thorough clinical examinations are necessary to rule out the cause, select appropriate treatment and predict visual outcome. Recurrence of bleeding should be monitored shortly after the hyphema is identified regardless of its severity. A monitoring of an elevation of the intraocular pressure is strongly recommended. Other common complications following hyphema are posterior synechia, peripheral anterior synechia, corneal blood staining and optic nerve atrophy with chronically elevated intraocular pressure.

## References

- Cho J., Jun B.K., Lee Y.J., Uhm K.B., 1998. Factors associated with the poor final visual outcome after traumatic hyphema. *Korean J. Ophthalmol.* 12(2): 122-129
- Collin B.K. and Moore C.P. 1999. Diseases and surgery of the canine anterior uvea. In: *Veterinary Ophthalmology*. 3rd Ed. Gelatt KN. Wolters Kluwer, Philadelphia. 779-781
- Sheppard J.D. 2006. Hyphema. Website: [www.emedicine.com/oph](http://www.emedicine.com/oph)