

The Thai Journal of Veterinary Medicine

Volume 37
Issue 2 June, 2007

Article 6

6-1-2007

Ophthalmology Snapshot

Nalinee Tuntivanich

Follow this and additional works at: <https://digital.car.chula.ac.th/tjvm>



Part of the [Veterinary Medicine Commons](#)

Recommended Citation

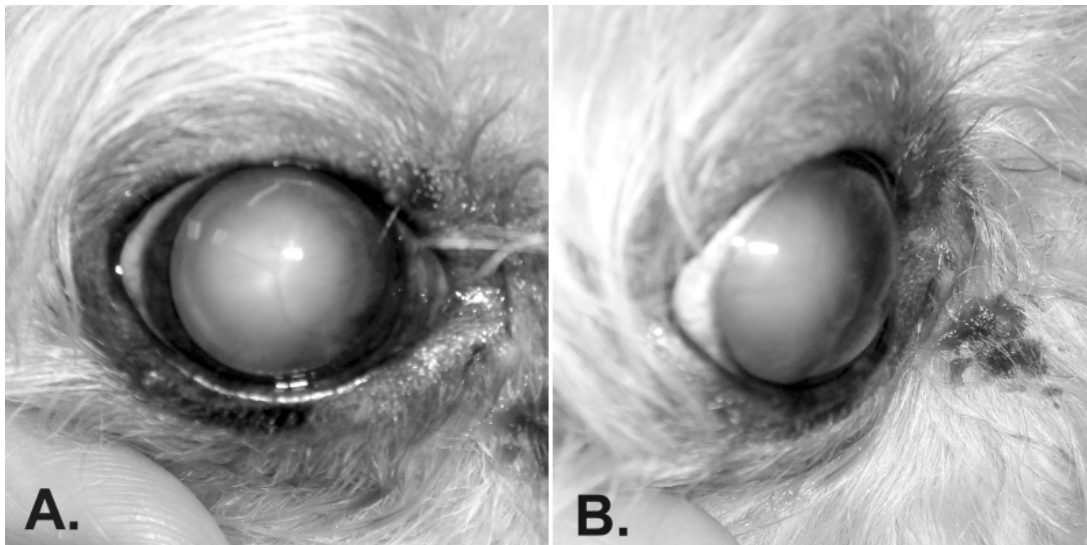
Tuntivanich, Nalinee (2007) "Ophthalmology Snapshot," *The Thai Journal of Veterinary Medicine*: Vol. 37: Iss. 2, Article 6.

Available at: <https://digital.car.chula.ac.th/tjvm/vol37/iss2/6>

This Other is brought to you for free and open access by the Chulalongkorn Journal Online (CUJO) at Chula Digital Collections. It has been accepted for inclusion in The Thai Journal of Veterinary Medicine by an authorized editor of Chula Digital Collections. For more information, please contact ChulaDC@car.chula.ac.th.

Ophthalmology Snapshot

Nalinee Tuntivanich



History :

A 9 yr-old female standard Poodle, Leah, had a history of bumping into objects around the house. The owner noticed that the dog had had this visual problem for several months and it had recently been worse. At the beginning, Leah was less active and reluctant to walk at the nighttime. By the time the owner had noticed “opacity” in Leah’s eyes, Leah started bumping into objects during the daytime. In addition, the owner also noticed that the opacity seemed larger and more obvious at nighttime compared to the daytime. Ophthalmic examination revealed negative menace response, positive dazzle reflex, and positive direct and consensual

pupillary light reflex in both eyes. Leah failed the obstacle course test in light and dark room conditions.

Questions :

1. What are differential diagnoses of “ocular opacity” of this case?
2. According to question 1, give an example of ophthalmic instruments that can be used for ophthalmic examination in this case, as well as their purposes of application.
3. What is your diagnosis and why?

Please turn to the next page for answers

Answers

1. When ocular opacity occurs, it can possibly involve 3 ocular organs:-

1.1 Cornea: corneal edema, corneal degeneration, generalized corneal opacity

1.2 Anterior chamber: fibrin formation, hypopyon, liquid aqueous, intraocular neoplasm

1.3 Lens: cataract, nuclear sclerosis

2. 2.1 Focal light: Strong and focusing light beam can be used to examine from adnexa to lens. However, oblique light beam is recommended for an examination of the anterior chamber and lens. Regardless of any ophthalmic instruments, pupil needs to be dilated to be able to inspect abnormality of the lens.

2.2 Ophthalmoscope: Different diameter of spherical light beam can be selected as well as a slit beam. Magnified view helps to enlarge the lesions. Any light aperture can be chosen for corneal and anterior chamber examinations however depth of the corneal lesion should be identified using a slit beam. The smallest light aperture is recommended for an examination of the

aqueous flare. Prior to ophthalmoscopic examination, the number on the instrument is set corresponding to location of the lesions examined.

3. Cataracts because

3.1 The opacity of the lens becomes larger after pupils are dilated at nighttime or after mydriatics application. In contrast, size of corneal lesions does not change related to size of the pupil.

3.2 Y-suture line in the front view (Fig 1A) is part of the lens.

3.3 Oblique view (Fig 1B) reveals opacity at the level of the lens, behind the anterior chamber, while the cornea and the anterior chamber are clear.

References

- Strubbe, D.T. and Gelatt, K.N., 1999. Ophthalmic examination and diagnostic procedures. In: *Veterinary Ophthalmology*. 3rd ed. K.N. Gelatt Wolters Kluwer, Philadelphia. 427-466.
- Williams, D.L., Heath, M.F. and Wallis, C., 2004. Prevalence of canine cataract: preliminary results of a cross-sectional study. *Vet. Ophthalmol.* 7(1): 29-35.