

6-1-2007

Success Rate and Postoperative Complications of Phacoemulsification in 25 Cataractous Eyes : a Retrospective Study in 20 Dogs (2003-2005)

Pasakorn Brikshavana

Follow this and additional works at: <https://digital.car.chula.ac.th/tjvm>



Part of the [Veterinary Medicine Commons](#)

Recommended Citation

Brikshavana, Pasakorn (2007) "Success Rate and Postoperative Complications of Phacoemulsification in 25 Cataractous Eyes : a Retrospective Study in 20 Dogs (2003-2005)," *The Thai Journal of Veterinary Medicine*: Vol. 37: Iss. 2, Article 4.

Available at: <https://digital.car.chula.ac.th/tjvm/vol37/iss2/4>

This Short Communication is brought to you for free and open access by the Chulalongkorn Journal Online (CUJO) at Chula Digital Collections. It has been accepted for inclusion in The Thai Journal of Veterinary Medicine by an authorized editor of Chula Digital Collections. For more information, please contact ChulaDC@car.chula.ac.th.

Success Rate and Postoperative Complications of Phacoemulsification in 25 Cataractous Eyes : a Retrospective Study in 20 Dogs (2003-2005)

Pasakorn Brikshavana

Abstract

Phacoemulsification was performed on 25 eyes of 20 dogs (7 females and 13 males) with a mean patient age \pm SD at the time of surgery of 8.12 ± 2.76 years (range 4-14.5 years). The medical records were reviewed for surgical outcome and postoperative complications. Success rate was calculated by determining the number of successful eyes divided by the total number of the eyes in the studied group. The results showed that restoration of functional vision was noted in 24/25 eyes at the end of the study. The success rate of this study was 96%. The most frequently observed complication during early postoperative period was uveitis, noted in 20/25 (80%) eyes. Other postoperative complications encountered include posterior capsular opacification in 10/25 (40%) eyes, postoperative ocular hypertension in 4/25 (16%) eyes, anterior or posterior synechiae in 3/25 (12%) eyes, corneal edema in 2/25 (8%) eyes, glaucoma in 1/25 (4%) eye, posterior capsule tear in 1/25 (4%) eye, and corneal ulcer in 1/25 (4%) eye. In conclusion, success rate is high for dogs following phacoemulsification and the significant postoperative complications are uveitis and posterior capsular opacification.

Keywords : complications, dog, phacoemulsification, success rate

Department of Surgery, Faculty of Veterinary Sciences, Chulalongkorn University, Pathumwan Bangkok 10330

บทคัดย่อ

อัตราประสบความสำเร็จและอาการแทรกซ้อนภายหลังการทำศัลยกรรมรักษาต้อกระจกด้วยวิธี Phacoemulsification จำนวน 25 ตา : การศึกษาย้อนหลังจำนวนสุนัข 20 ตัว (2003-2005)

ภาสกร พุกกะวัน

การศึกษาย้อนหลังอัตราประสบความสำเร็จและอาการแทรกซ้อนภายหลังการทำศัลยกรรมรักษาต้อกระจกด้วยวิธี Phacoemulsification จำนวน 25 ตา จากสุนัข 20 ตัว (เพศเมีย 7 ตัวและเพศผู้ 13 ตัว) อายุเฉลี่ยของสุนัขขณะเข้ารับการผ่าตัด ± ค่าเบี่ยงเบนมาตรฐานเท่ากับ 8.12 ± 2.76 ปี พิสัย (4-14.5 ปี) ผลการศึกษาพบว่าภายหลังการทำศัลยกรรม 24 ตา จาก 25 ตา กลับมามองเห็นและการมองเห็นยังคงอยู่ตลอดระยะเวลาศึกษา อัตราการประสบความสำเร็จเท่ากับร้อยละ 96 อาการแทรกซ้อนที่พบได้ในระยะแรกภายหลังการทำศัลยกรรม คือ ยูเวียอักเสบพบใน 20 ตาจาก 25 ตา (ร้อยละ 80) ส่วนอาการแทรกซ้อนอื่นที่พบ คือ การที่บวมแดงของถุงหุ้มแก้วตาด้านหลังพบใน 10 ตาจาก 25 ตา (ร้อยละ 40) ความดันภายในลูกตาสูงภายหลังทำศัลยกรรมพบใน 4 ตาจาก 25 ตา (ร้อยละ 16) ม่านต้ายึดติดกับกระจกตาหรือถุงหุ้มแก้วตาด้านหลังพบใน 3 ตาจาก 25 ตา (ร้อยละ 12) กระจกตาวมน้ำพบใน 2 ตาจาก 25 ตา (ร้อยละ 8) ต้อหินพบใน 1 ตาจาก 25 ตา (ร้อยละ 4) ถุงหุ้มแก้วตาด้านหลังฉีกพบใน 1 ตาจาก 25 ตา (ร้อยละ 4) และกระจกตาเป็นแผลพบใน 1 ตาจาก 25 ตา (ร้อยละ 4) โดยสรุปในสุนัขที่ทำศัลยกรรมรักษาต้อกระจกด้วยวิธี Phacoemulsification มีอัตราการประสบความสำเร็จที่สูง อาการแทรกซ้อนที่พบได้บ่อยคือ ยูเวียอักเสบและการที่บวมแดงของถุงหุ้มแก้วตาด้านหลัง

คำสำคัญ : อาการแทรกซ้อน สุนัข phacoemulsification อัตราประสบความสำเร็จ

ภาควิชาสัตวศาสตร์ คณะสัตวแพทยศาสตร์ จุฬาลงกรณ์มหาวิทยาลัย ปทุมวัน กรุงเทพฯ 10330
ผู้รับผิดชอบบทความ

Introduction

One of the most important advances in cataract surgery is phacoemulsification. Extracapsular cataract extraction (ECCE) requires a relatively large wound that results in a long healing process and slow visual recovery but phacoemulsification requires a smaller surgical wound, resulting in a shorter healing process, less against-the-rule astigmatism, and more rapid visual recovery (Azar and Rumelt, 2000). Confronted with the results of a recent poll of the American Society of Cataract and Refractive Surgery, which showed phacoemulsification as the preferred method of cataract extraction by more than 90% of ophthalmic surgeons interviewed (Kelman et al., 1999). In veterinary medicine, surgical removal of cataracts is the treatment of choice if restoration of vision is desired. There are several techniques that are described and are being used to remove cataractous lens in veterinary practice. However, phacoemulsification is considered

the treatment of choice among of most surgeons (Moore et al., 2003). In the early days of veterinary cataract surgery, Intracapsular cataract extraction (ICCE) was the technique of choice. The tearing of the lens zonules or enzymatic destruction with chymotrypsin permitted the removal of the lens within its capsule, thus avoiding the spillage of lens material into the globe but allowing the anterior displacement of vitreous. ECCE has been the standard procedure for many years and recently phacoemulsification has become a common method for the removal of the cataractous lens (Williams et al., 1996). Cataract removal using phacoemulsification is achieved by ultrasonic fragmentation and aspiration of the lens material. The tip of the phacoemulsification handpiece is composed of a hollow approximately 1mm titanium needle that transmits vibrations at a high speed (30,000 to 60,000 cycle / sec) to emulsify the cataract. The aspiration of nuclear fragments occurs through the hollow tip.

When the tip engages the lens material, a vacuum is built up that facilitates aspiration of the lens material (Azar and Rumelt, 2000). The objective of small incision phacoemulsification is to break the lens into small pieces so that it can be emulsified and removed as quickly and atraumatically as possible. Two main techniques are used to accomplish this objective. In one method, termed the two-handed technique, one hand manipulates the phaco handpiece while the other manipulates a second instrument inserted into the eye through a side port incision. The second instrument is used to manipulate the lens and stabilize the globe. In the one-handed technique, only the phaco handpiece is introduced into the eye (Glover and Constantinescu, 1997). Approximately 4000 to 5000 cataract surgeries are performed annually in the United States and the majority of these procedures are by phacoemulsification (Gilger, 1997). In Thailand, the phacoemulsification technique has been recently used and there has been no scientific report ever conducted before. The purpose of this retrospective study is to report the success rate of phacoemulsification without intraocular lens implantation in dogs and to document the postoperative complications.

Materials and Methods

The medical record of dogs on which phacoemulsification was performed by the author at the small animal teaching hospital, Chulalongkorn university, Bangkok, Thailand between January 2003 and December 2005 were reviewed. All dogs received thorough ophthalmic examination, including ocular ultrasonography and IOP measurement with applanation tonometer (Tono-pen XL®, Medtronic) and routine physical and laboratory examination before surgery. Cataracts were diagnosed with direct ophthalmoscopy and slit lamp biomicroscopy (SL-14, Kowa). None of the dogs had menace response but normal pupillary light and dazzle reflexes. Cataracts were classified according to type (juvenile, adult, senile, or diabetic) and stage (immature, mature, or hypermature) at the time of surgery.

Phacoemulsification was performed on 25 eyes of 20 dogs (7 females and 13 males) with a mean patient age \pm SD at the time of surgery of 8.12 ± 2.76 years (range 4–14.5 years). There were 9 Poodles (11 eyes), 7 mixed breeds (10 eyes), 3 English cocker spaniels, (3 eyes) and 1 Shitzu (1 eye). The type of the cataract was determined to be juvenile in 3/25 (12%), adult in 8/25 (32%), senile in 12/25 (48%), and diabetic in 2/25 (8%) eyes. Cataracts were staged as mature in 13/25 (52%), and hypermature in 12/25 (48%) eyes (Table 1). The mean preoperative intraocular pressure (IOP) \pm SD was 12.75 ± 3.34 mmHg. Only cases with a minimum of 8 weeks postoperative evaluation were included in the study.

Tobramycin 0.3% (Tobrex®, Alcon Laboratories) 4 times daily, ketorolac tromethamine 0.5% (Acular®, Allergan) 4 times daily and atropine sulfate 1% (Isoptoatropine®, Alcon Laboratories) 2 times daily were administered topically to the affected eye beginning 3 days before surgery. Beginning 2 hours before surgery, tropicamide 1% (Mydriacyl®, Alcon laboratories), tobramycin 0.3% and ketorolac tromethamine 0.5% were administered topically every 15 minutes until surgery.

At surgery, general anesthesia is required. The type of anesthesia, drug used, and dosage depended on the signalment and health status of the patient. Preanesthetic drugs frequently used were acepromazine maleate (Sedastress®, Farvet) 0.02 mg/kg and morphine sulfate pentahydrate (Morphine sulfate, Thai FDA) 0.5 mg/kg intramuscularly (IM). Anesthesia is induced by use of propofol (Pofol®, Dongkook Pharm.) 4 mg/kg intravenously (IV). Isoflurane (Terrel®, Minrad Inc.) and oxygen are used to maintain the anesthesia. After induction, the hair of the eyelids were clipped off at least 4 cm. from the eyelid margins, the loose hair was gently irrigated from the ocular surface with normal saline solution. The patients were placed in lateral recumbency, with heads positioned carefully with metal rings. 1% povidone iodine solution was used to scrub periocular tissue. In addition, sterile cotton-tipped applicators dipped in the 1% povidone iodine solution were used to gently

clean out the conjunctival sac then rinsed ocular surface with normal saline solution. Cefazolin sodium (Zefa M.H.[®], M&H Manufacturing) 25 mg/kg and dexamethasone sodium phosphate (Lodexa-4[®], L.B.S. laboratory) 0.5 mg/kg were administered intravenously. Diabetic patients were treated with carprofen (Rimadyl[®], Vericore) 2.2 mg/kg in lieu of dexamethasone. Atracurium besylate (Tracrium[®], Glaxo Smithkline) 0.3 mg/kg was administered just before surgery. Phacoemulsification was performed by one surgeon (the author) with the aid of an operating microscope and using a standard two-handed technique.

After surgery, cefazolin 25 mg/kg and dexamethasone 0.5 mg/kg were administered IM for 4 days then cephalexin (Ibilex[®], Siam pharmaceutical) 25 mg/kg and prednisolone (Prednisolone, New life pharma.) 0.5 mg/kg, orally twice daily for 3 days. Diabetic patients were treated with carprofen 4.4 mg/kg subcutaneously for 4 days then 2.2 mg/kg, orally twice daily for 3 days instead of dexamethasone. Tobramycin 0.3% every hours, fluorometholone acetate 0.1% (Flarex[®], Alcon laboratories) 4 to 6 times daily and atropine sulfate 1% 2 times daily were administered topically beginning the day of surgery and, thereafter, for 7 days. After that the frequency of tobramycin and fluorometholone acetate was decreased to 4 times daily for 1 month after surgery. Postoperative evaluations were performed at 1,2,3,4,7,14,21,28,35,42 and 60 days postoperatively.

Records for all dogs undergoing phacoemulsification were further reviewed for postoperative complications, including uveitis, postoperative ocular hypertension (defined as IOP >25 mmHg within 72 hours after surgery), glaucoma, posterior capsule opacification, posterior capsular tears, anterior displacement of vitreous, synechiae, retinal detachment, bacterial endophthalmitis and persistent corneal edema. A successful surgical outcome was defined as restoration of functional vision, assessed by response to a menacing gesture and the ability to navigate an obstacle course. Success rate was calculated by determining the number of successful eyes divided by

the total number of the eyes in the studied group.

Results and Discussion

Postoperative success rate for all eyes and for each cataract type and stage are summarized in Table 2. At first day postoperative, improvement of functional vision was noted in 20/25 (80%) eyes. 24/25 (96%) eyes regained functional vision at days 2 to 6 and remained through out the study period (60 days). Vision was not improved in 1/25 (4%) eye and the reason for poor vision was secondary glaucoma. The mean postoperative intraocular pressure \pm SD at the end of study period was 14.05 ± 4.98 mmHg (range 9-29 mmHg). The overall success rate of this study was 96%.

The postoperative complications for all eyes are showed in figure 1. The most frequently observed complication within the early postoperative period (within 48 hours after surgery) was uveitis, noted in 20/25 (80%) eyes. Other postoperative complications encountered included posterior capsule opacification (Fig. 2) 10/25 (40%) eyes, postoperative ocular hypertension 4/25 (16%) eyes, anterior or posterior synechiae 3/25 (12%) eyes, corneal edema 2/25 (8%) eyes, glaucoma 1/25 (4%) eye, posterior capsular tears 1/25 (4%) eye and corneal ulcer 1/25 (4%) eye.

Phacoemulsification is an ideal procedure for cataract extraction in both human and veterinary practices. Despite currently reported short-term success rates exceeding 90% (Sigle and Nasisse, 2006). In the recent study the overall surgical success rate of phacoemulsification without intraocular lens implantation of this study was 96%. In contrast to the other techniques, Davidson et al. (1990) performed a retrospective of postoperative results of 113 unilateral extracapsular cataract extraction (ECCE) in dogs. Restoration or improvement of functional vision was achieved in only 79.6% of the eyes at 4 to 6 weeks postoperatively. The technique used in this study was two-handed technique phacoemulsification. The principle advantage of two-handed technique is a greater

flexibility in lens manipulation afforded by having two instruments in the eye. Theoretically the two-handed technique results in quicker and safer surgery because the lens can be cracked without the need for sculpting near the posterior capsule, and the lens can be fed to the phaco tip. This technique also allows for a larger diameter capsulorrhexis, because the second instrument can keep large fragments of lens material out of the anterior chamber. A major disadvantage of two-handed technique is that it is technically more demanding, because two separate instruments are in the eye (Glover and Constantinescu, 1997).

The potential complications of canine phacoemulsification surgery are numerous and include corneal edema, corneal ulceration, uveitis, glaucoma, posterior capsule opacification and lens fiber regrowth, posterior capsular tears, vitreous loss, lens drop, retinal detachment, endophthalmitis, and wound dehiscence. In this study, corneal edema, corneal ulceration posterior capsular tear, vitreous loss, lens drop, retinal detachment, endophthalmitis, and wound dehiscence were an infrequent complications. On the other hand, uveitis and posterior capsule opacification were common complications.

Uveitis is a common cause of secondary glaucoma following cataract surgery. In this study, only a mild uveitis was seen in the operated eyes in the first 3 days after surgery. Phacoemulsification is reported to reduce the severity of postoperative lens induced uveitis due to shorter surgical time and more adequate removal of lens cortex than other techniques (Wilkie and Wolf, 1990). From the recent study done by Moore et al. (2003), the most frequently observed complication within 48 hours postoperative was uveitis, recorded in 72% of eyes. Phacolytic uveitis is a lymphocytic-plasmacytic anterior uveitis that may occur secondary to release of lens protein through an intact lens capsule (Van der Woerd, 2000). The presence of phacolytic uveitis significantly reduces both short-term and long-term success rate of cataract surgery in veterinary medicine, even when

the uveitis appears to be controlled prior to surgery (Van der Woerd et al., 1992). Intraoperative complications are more common in eyes with a history of phacolytic uveitis than in non affected eyes. Performing cataract surgery when the cataract is either immature or mature prior to the onset of phacolytic uveitis may prevent short-term and long-term complications, because phacolytic uveitis is most commonly seen in eyes with hypermature cataracts (Van der Woerd, 2000).

Posterior capsule opacification (PCO) is the most common complication of modern cataract surgery (Bras et al., 2006 ; Sigle and Nasisse, 2006) that occurs in up to 50% of human cases and is the second most common cause of blindness (Bras et al., 2006). PCO is caused by proliferation and migration of residual lens epithelium, fibroblasts, macrophages, and iris-derived pigment cells on the posterior capsule, which can impair the quality of vision over time (Bras et al., 2006). In this study, PCO was found in 40% of operated eyes which is lower than previously reported at 69% (Sigle and Nasisse, 2006).

Glaucoma has been defined as an increase in IOP that is incompatible with the health and function of the retina and optic nerve (Gelatt and Brooks, 1999). Transient increases in IOP within 72 hours of the completion of cataract surgery is referred to as postoperative ocular hypertension (POH) (Smith et al., 1996). POH is not a true glaucoma, as there is no detectable long term evidence of retinal and optic nerve damage causing vision loss. In contrast, glaucoma may develop days to month after cataract removal (Biros et al., 2000). The postoperative glaucoma in the current study was found in 4% of operated eyes which is lower than previously reported at 16.8% (Biros et al., 2000). But in the recent study, the prevalence of postoperative glaucoma was less than 10% (Sigle and Nasisse, 2006). On the other hand, POH was identified in 16% of operated eyes and one eye within this group had developed secondary glaucoma later. In contrast to a previous study done by Smith et al.(1996), the incidence of POH was as high as 48.9%. But in the recent study, the

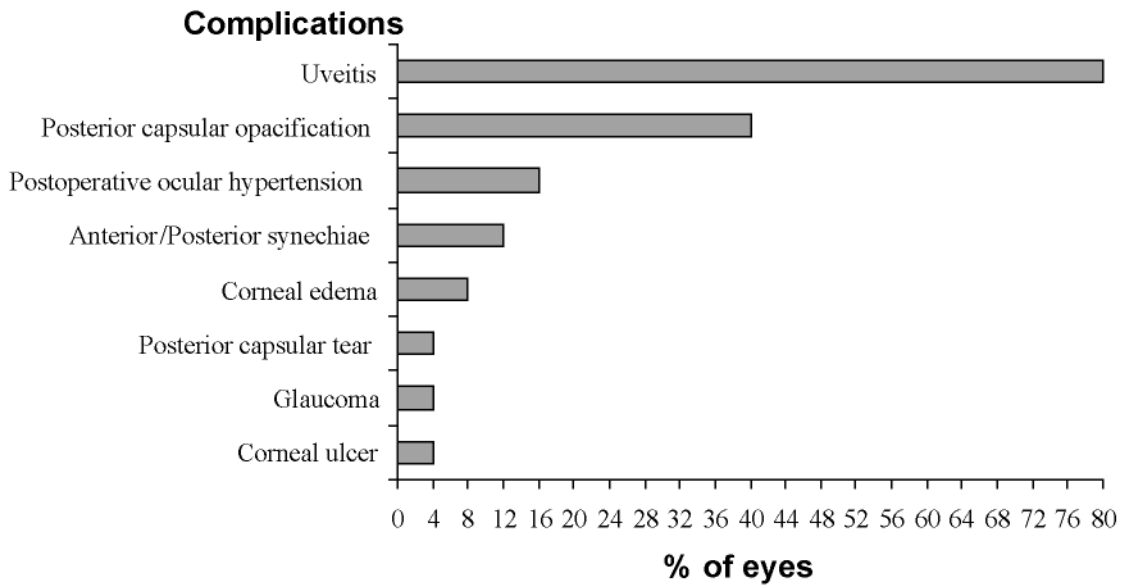


Figure 1 Postoperative complications in 25 operated eyes.

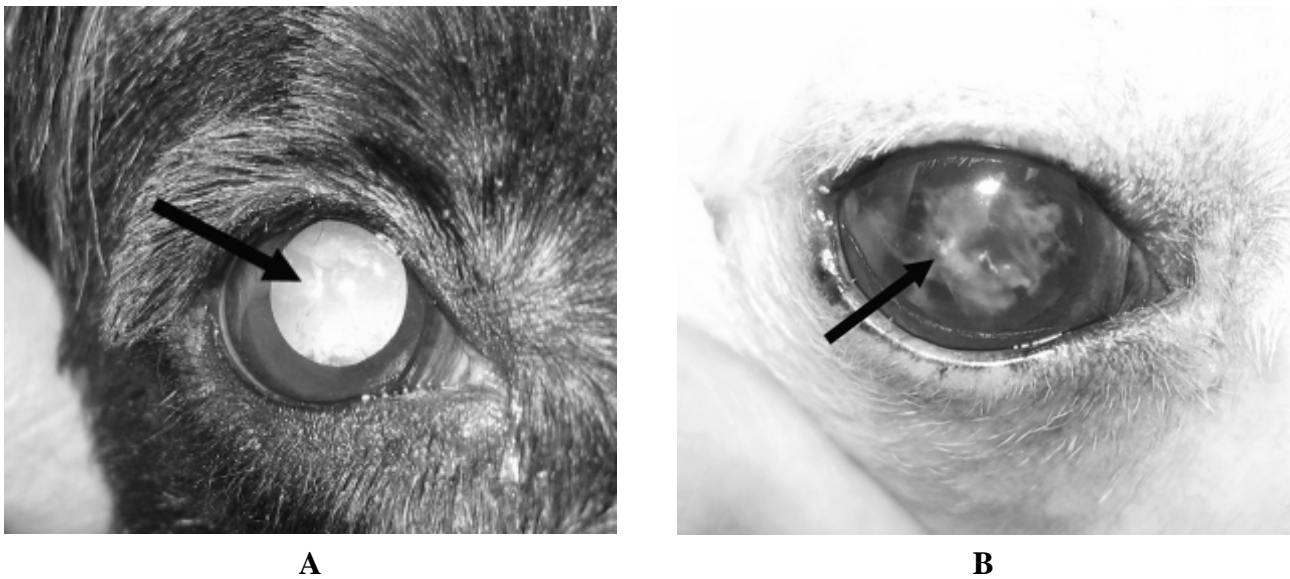


Figure 2 A. Three weeks postoperatively right eye of eye number 23 (adult / mature cataract), there was evidence of mild posterior capsular opacification (black arrow). This dog had aphakic vision.
 B. First week postoperatively right eye of eye number 22 (juvenile / hypermature cataract), there was evidence of severe posterior capsular opacification (black arrow) with synechiae at 1 o'clock. This dog had aphakic vision.

Table 1 Preoperative information on the 25 operated eyes.

Breed	Sex		Type of cataract				Stage of cataract		
	Female	Male	Juvenile	Adult	Senile	Diabetic	Immature	Mature	Hypermature
Poodle	4	7	1	3	5	2	-	6	5
Mixed breed	3	7	2	4	4	-	-	3	7
Cocker spaniel	1	2	-	1	2	-	-	3	-
Shihtzu	1	-	-	-	1	-	-	1	-
Total	9	16	3	8	12	2	0	13	12

Table 2 Surgical success rate for each cataract type and stage.

	Number of successful eyes / Total eyes (%)	
Type		
Juvenile	3/3	(100)
Adult	8/8	(100)
Senile	11/12	(91.67)
Diabetic	2/2	(100)
Stage		
Mature	13/13	(100)
Hyper mature	11/12	(91.67)

incidence of POH was only 20% (Chahory et al., 2003). POH is a relatively frequent complication following canine cataract surgery. Development of POH does not correlated with sex, stage of cataract, type of surgical procedure, intraocular lens placement, postoperative lens-induced uveitis, posterior lens capsule tears or vitrectomy. However, eyes operated on by phacoemulsification developed POH significantly more rapidly than those operated on by ECCE (Chahory et al., 2003). On the other hand, the risk of secondary glaucoma from eyes operated on by phacoemulsification was less than those operated on by ECCE (Gelatt and Mackay, 2004). Numerous studies have tried to explain the mechanisms by which acute ocular pressure increases in the first hours after surgery. The possible hypotheses include trabecular meshwork swelling, aqueous outflow obstruction by zonular fragments, the action of visco-elastic materials, residual lens particles, inflammatory debris, soluble lens proteins, pigment or viscous aqueous or vitreous plasmoid humor (Chahory et al., 2003).

In one study 34 percent of eyes had postoperative synechiae, though only 5 percent of the eyes were reported to have clinical uveitis (Williams et al., 1996). In the current study, the presence of focal anterior or posterior synechiae was found in 3 eyes (12%). Fibrin deposition in the anterior chamber and on the remaining lens capsule was noted in all affected eye in the first few days after surgery. This may result in the adhesion of the iris to other structure (Severin, 1995).

The viability of the corneal endothelium is critically important to the success of cataract surgery. Damage to the corneal endothelium may result in corneal edema. In the current study, small area of corneal edema at the incision site were found in two eyes (8%). Suggested causes for endothelial damage associated with phacoemulsification include toxin and mechanical effects of large volumes of irrigating solutions, ultrasonic turbulence, ricocheting nuclear fragments, instrument contact, cavitation bubbles and severe intraocular inflammation (Moore et al., 2003)

Posterior capsular tears are a significant intra-operative complication of cataract surgery, especially in the early stages of learning. The tissue is particularly fragile in the dog and an incidence of up to 16.5% has been reported (Williams et al., 1996). The reported incidence of posterior capsule tear in humans ranges from 0.05 to 10% (Johnstone and Ward, 2005). In this study, a small posterior capsular tears was recorded in one eye (4%). Posterior capsular tears usually occur during deep sculpting or when polishing the posterior during cortex aspiration. Sharp nuclear fragments can also lacerate the posterior capsule as the nucleus is rotated within the bag. Although vitreous presentation may occur with these tears, it does not automatically signify the need for a vitrectomy. When small tears are encountered, the vitreous herniation may be slight and phacoemulsification can usually proceed to completion in an unaffected area (Glover and Constantinescu, 1997).

Corneal ulcers were infrequently seen and occurred in one dog with skin disease. This would suggest that dogs with healthy corneas were not likely to develop ulcers postoperatively unless a factor causing ocular irritation was also present.

In conclusion, the success rate is high for dogs following phacoemulsification and the significant postoperative complication are uveitis and posterior capsular opacification. Phacoemulsification requires a smaller surgical wound, resulting in a shorter healing process, fewer complications, more rapid visual recovery, and a higher success rate than the other techniques. But it is costly and requires considerable experience in usage.

References

- Azar, D.T. and Rumelt, S. 2000. Phacoemulsification. In: Principles and Practice of Ophthalmology. 2nd ed. D.M. Albert and F.A. Jakobiec (eds.). Philadelphia : W.B. Saunders. 1500-1513.
- Biros, D.J., Gelatt, K.N., Brooks, D.E., Kubilis, P.S., Andrew, S.E., Strubbe, D.T. and Whigham, H.M. 2000. Development of glaucoma after cataract surgery in dogs : 220 cases (1987-1998). *J. Am. Vet. Med. Assoc.* 216(11): 1780-1786.
- Bras, I.D., Colitz, C.M.H., Saville, W.J.A. and Gemensky-Metzler, A.J. 2006. Posterior capsular opacification in diabetic and nondiabetic canine patients following cataract surgery. *Vet. Ophthalmol.* 9(5): 317-327.
- Chahory, S., Clerc, B., Guez, J. and Sanaa, M. 2003. Intraocular pressure development after cataract surgery : a prospective study in 50 dogs (1998-2000). *Vet. Ophthalmol.* 6(2): 105-112.
- Davidson, M.G., Nasissse, M.P., Rusnak, I.M., Corbett, W.T. and English, R.V. 1990. Success rates of unilateral vs. bilateral cataract extraction in dogs. *Vet. Surg.* 19(3): 232-236.
- Gelatt, K.N. and Brooks, D.E. 1999. The canine glaucoma. In: *Veterinary Ophthalmology*. 3rd ed. K.N. Gelatt (ed.). Philadelphia : Williams & Wilkins. 701-754
- Gelatt, K.N. and Mackay, E.O. 2004. Secondary glaucomas in the dog in North America. *Vet. Ophthalmol.* 7(4): 245-259.
- Gilger, B.C. 1997. Phacoemulsification ; Technology and Fundamentals. *Vet. Clin. North. Am. Small Anim. Pract.* 27(5): 1131-1141.
- Glover, T.D. and Constantinescu, G.M. 1997. Surgery for cataracts. *Vet. Clin. North. Am. Small Anim. Pract.* 27(5): 1143-1173.
- Johnstone, N. and Ward, D.A. 2005. The incidence of posterior capsule disruption during phacoemulsification and associated postoperative complication rate in dogs: 244 eyes (1995-2002). *Vet. Ophthalmol.* 8(1): 47-50.
- Kelman, C.D., Creed, K., Mackool, R.J., Fine, I.H., Sanan, A., Koch, D.D., Koch, P.S., Dodick, J.M., Beade, P.E. and Carty, J.B., Jr. 1999. Phacoemulsification. In: *Atlas of Ophthalmology*. R.K. Parrish II (ed.). Philadelphia : Current Medicine. 247-255.
- Moore, D.L., McLellan, G.J. and Dubielzig R.R. 2003. A study of morphology of canine eyes enucleated or eviscerated due to complications following phacoemulsification. *Vet. Ophthalmol.* 6(3): 219-226.
- Severin, G.A. 1995. Anterior uvea. In : *Severin's Veterinary Ophthalmology Notes*. 3rd ed. Fort Collins : Design Pointe Communication. 359-375
- Sigle, K.J. and Nasissse, M.P. 2006. Long-term complications after phacoemulsification for cataract removal in dogs: 172 cases (1995-2002). *J. Am. Vet. Med. Assoc.* 228(1): 74-79.
- Smith, P.J., Brooks, D.E., Lazarus, J.A., Kubilis, P.S. and Gelatt, K.N. 1996. Ocular hypertension following cataract surgery in dogs : 139 cases (1992-1993). *J. Am. Vet. Med. Assoc.* 209(1): 105-111.
- Van der Woerd, A. 2000. Lens-induced uveitis. *Vet. Ophthalmol.* 3(4): 227-234.
- Van der Woerd, A., Nasissse, M.P. and Davison, M.G. 1992. Lens-induced uveitis in dogs: 151 cases 1985-1990. *J. Am. Vet. Med. Assoc.* 201(6): 921-926.
- Williams, D.L., Boydell, I.P. and Long, R.D. 1996. Current concepts in the management of canine cataract: a survey of techniques used by surgeons in Britain, Europe and the USA and a review of recent literature. *Vet. Rec.* 138: 347-353.
- Wilkie, D.A. and Wolf, D.E. 1990. Cataract surgery. In: *Current Techniques in Small Animal Surgery*. 3rd ed. M.J. Bojarb (ed.). Philadelphia : Lea & Febiger. 98-104.