

3-1-2007

Pathological Study of Helicobacter spp. Infection in Pig Stomachs

Nopadon Pirarat

Veerasak Sada

Supradit Wangnaitham

Boonmee Sunyasootcharee

Follow this and additional works at: <https://digital.car.chula.ac.th/tjvm>



Part of the [Veterinary Medicine Commons](#)

Recommended Citation

Pirarat, Nopadon; Sada, Veerasak; Wangnaitham, Supradit; and Sunyasootcharee, Boonmee (2007) "Pathological Study of Helicobacter spp. Infection in Pig Stomachs," *The Thai Journal of Veterinary Medicine*: Vol. 37: Iss. 1, Article 4.

DOI: <https://doi.org/10.56808/2985-1130.2069>

Available at: <https://digital.car.chula.ac.th/tjvm/vol37/iss1/4>

This Article is brought to you for free and open access by the Chulalongkorn Journal Online (CUJO) at Chula Digital Collections. It has been accepted for inclusion in The Thai Journal of Veterinary Medicine by an authorized editor of Chula Digital Collections. For more information, please contact ChulaDC@car.chula.ac.th.

Pathological Study of *Helicobacter spp.* Infection in Pig Stomachs

Nopadon Pirarat^{1*} Veerasak Sada² Supradit Wangnaitham¹
Boonmee Sunyasootcharee¹

Abstract

A pathological study of *Helicobacter spp.* infection in pigs was performed to determine the incidence of *Helicobacter spp.* infection, and to define the relationship between *Helicobacter spp.* infection and the histopathological changes of gastric mucosa in pigs, using Warthin Starry stain and immunohistochemistry. A total of 115 biopsies of the cardia, fundus, body and pyloric antrum of swine (mean weight 150 kg) obtained from slaughterhouses in Nakornpathom province (Thailand) were investigated. Histopathological results of the cardia region showed thickening of mucosa 54.78% (63/115), vacuolated degeneration of the epithelium 83.47% (96/115), lymphoid aggregation 74.78% (86/115), inflammatory cells infiltration 38.26% (44/115) and neovascularized granulation tissue 10.43% (12/115). The presence of *Helicobacter spp.* by Warthin Starry stain and immunohistochemistry was 16.52% and 13.91% positive respectively. *Helicobacter spp.* was mostly seen in the epithelial surface of the pars esophageal region of stomach. There was no statistical difference in the mean histopathological scores of glandular regions (fundus, body and pyloric antrum) between *Helicobacter spp.* positive and *Helicobacter spp.* negative samples. The results showed no correlation between the histopathological changes in pig stomachs and the presence of *Helicobacter spp.* This study demonstrated the colonization of *Helicobacter spp.* in pig stomachs in Thailand. However, the bacteria seem not to be a major cause of gastritis or gastric ulcer in swine in Thailand

Keywords : Immunohistochemistry, *Helicobacter spp.*, histopathology, pig, stomach

¹Department of Pathology, Faculty of Veterinary Science, Chulalongkorn University, Bangkok 10330.

²Clinic for Swine, Faculty of Veterinary Medicine, Mahanakorn University of Technology, Bangkok

*Corresponding author

บทคัดย่อ

การศึกษาลักษณะทางพยาธิวิทยาของกระเพาะอาหารสุกรที่ติดเชื้อแบคทีเรีย *Helicobacter spp.*

นพดล พิพารัตน์* วีระศักดิ์ สะดะ² สุประดิษฐ์ หวังในธรรม¹ และ บุญมี สัญญสุจจารี¹

ศึกษาลักษณะทางพยาธิวิทยาของกระเพาะอาหารสุกรที่ติดเชื้อแบคทีเรีย *Helicobacter spp.* เพื่อหาอุบัติการณ์การติดเชื้อแบคทีเรีย *Helicobacter spp.* ในกระเพาะอาหารของสุกรและหาความสัมพันธ์ระหว่างลักษณะทางจุลพยาธิวิทยาของกระเพาะอาหารสุกรและการติดเชื้อแบคทีเรีย *Helicobacter spp.* โดยใช้เทคนิคการย้อมสีพิเศษ Warthin Starry และเทคนิคอิมมูโนฮิสโตเคมี เก็บตัวอย่างชิ้นเนื้อกระเพาะอาหารสุกร 4 บริเวณ ได้แก่ cardia fundus body และ pyloric antrum จากโรงฆ่าสัตว์ในเขตจังหวัดนครปฐม ประเทศไทย สุกรน้ำหนักเฉลี่ยประมาณ 150 กิโลกรัม จำนวน 115 ตัวอย่าง ผลการศึกษาลักษณะการเปลี่ยนแปลงทางพยาธิวิทยาของกระเพาะอาหารส่วน cardia พบการหนาตัวของชั้นเยื่อ 54.78% (63/115) เซลล์เยื่อบุผิว บวมหน้า 83.47% (96/115) พบลักษณะ lymphoid follicles 74.78% (86/115) การแทรกตัวของเซลล์อักเสบ 38.26% (44/115) และการเจริญของหลอดเลือดใหม่และเนื้อเยื่อ granulation tissue ในบริเวณชั้นเยื่อบุผิว 10.43% (12/115) อุบัติการณ์การปรากฏของเชื้อแบคทีเรีย *Helicobacter spp.* ด้วยเทคนิคการย้อมสีพิเศษ Warthin starry และเทคนิคอิมมูโนฮิสโตเคมี คิดเป็น 16.52% และ 13.91% ตามลำดับ ตรวจพบเชื้อแบคทีเรีย *Helicobacter spp.* มากที่สุดในส่วนของเยื่อบุผิวบริเวณ pars esophagea ค่าเฉลี่ยการเปลี่ยนแปลงของลักษณะทางจุลพยาธิวิทยาของกระเพาะอาหารส่วน fundus body และ pyloric antrum ที่พบเชื้อแบคทีเรียและไม่พบเชื้อแบคทีเรียไม่มีความแตกต่างกัน ผลการศึกษาลักษณะการเปลี่ยนแปลงทางจุลพยาธิวิทยาของกระเพาะอาหารไม่มีความสัมพันธ์กับการปรากฏของเชื้อแบคทีเรีย *Helicobacter spp.* การศึกษาในครั้งนี้แสดงการตรวจพบเชื้อแบคทีเรีย *Helicobacter spp.* ได้ในกระเพาะอาหารของสุกรในประเทศไทย แต่อย่างไรก็ตามแบคทีเรียนี้ไม่ใช่สาเหตุหลักของการเกิดกระเพาะอาหารอักเสบหรือแผลหลุมของกระเพาะอาหารในสุกรในประเทศไทย

คำสำคัญ: อิมมูโนฮิสโตเคมี *Helicobacter spp.* จุลพยาธิวิทยา สุกร กระเพาะอาหาร

¹หน่วยพยาธิวิทยา คณะสัตวแพทยศาสตร์ จุฬาลงกรณ์มหาวิทยาลัย

²สาขาคลินิกสำหรับสุกร คณะสัตวแพทยศาสตร์ มหาวิทยาลัยเทคโนโลยีมหานคร

*ผู้รับผิดชอบบทความ

Introduction

Gastric ulceration of the pars esophagia is a chronic multifactorial problem in the pig industry worldwide, including Thailand. The affected swine shows clinical signs of anorexia, acute or chronic blood loss anemia, retarded growth and eventual death. The clinical signs associated with gastric ulcers are commonly seen in breeding and growing pigs, leading to great economic loss to industrial pig farms (Groote et al., 2000; Doster, 2000). The lesion develops from the complex interaction of stress, dietary size, gastric fluidity or acidity, dietary carbohydrate content, intoxication, hormonal and seasonal change, infections, as well as the presence of certain

species of commensal gastric organisms (Cantet et al., 1999). The exact etiology remains unknown. Until the spiral bacterium *Helicobacter pylori* was reported in 1982 as being the major predisposing factor in the pathogenesis of gastritis, gastric ulcers, gastric lymphoma and gastric adenocarcinoma in humans. Since then, the study of gastric *Helicobacter spp.* in animals has dramatically increased (McGovern et al., 2001; Nakamura et al., 1998). For instance, the presence of *H. mustelae* in ferrets with gastritis and gastric ulcers, *H. acinonyx* in cheetahs with severe gastritis, and *H. heilmannii* in pigs with gastric ulcers has been reported (Laurence et al., 1995).

Helicobacters are curved to spiral shaped or sometimes coccoid, gram negative bacteria that inhabit the gastric mucosal epithelium of animals and humans (Grasso et al., 1996). *Helicobacter* species in pig stomachs have been identified by different diagnostic methods, including urease test, histology, immunohistochemistry and Polymerase chain reaction (PCR). These spiral bacteria are classified into several species using 16S rRNA sequencing DNA hybridization and electron microscopy (Cantet et al., 1999). *Helicobacter* species reported from pigs were mainly *Candidatus H. suis*, *H. heilmannii* type 1 and type 2 (Cantet et al., 1999; Mendes et al., 1991). Because *H. pylori* and *H. heilmannii* have been observed in human gastric pathology, both *Helicobacter* species can be recognized as zoonotic pathogens and pigs could possibly be a potential source for human *Helicobacter* infection (Choi et al., 2001). Investigation of the relationship of gastric disease to *Helicobacter spp.* in animals, the pathogenesis, the pathological lesions and the zoonotic risk are still being discussed (Simpson et al., 2000).

Swine gastric *Helicobacter spp.* infection has not been reported in Thailand. The aims of this study were to demonstrate the incidence and to define the relationship between *Helicobacter spp.* infection and the histopathological change of gastric mucosa in pigs in Thailand.

Materials and Methods

Histopathology

A total of 115 stomach samples of swine obtained from slaughterhouses in Nakornpathom province (Thailand) (mean weight 150 kg) during October 2001 to June 2002 were collected. Biopsy samples from the cardia, fundus, body and pyloric antrum in each stomach were slightly excised into 1 cm long pieces. All pieces of gastric tissue were immediately fixed in 10% neutral buffer formalin for 24-48 hrs, dehydrated in an alcohol-xylene series and embedded in paraffin wax. Cut sections of 4 µm thickness were stained with

Haematoxylin and eosin (H&E) for routine histopathological examination and Warthin Starry silver stain (WS) for the *in situ* detection of spiral bacteria. The histopathological score of glandular regions were graded according to following criteria; 0 : normal; 0-10 inflammatory cells (i.e. lymphocytes, plasma cells and macrophages) per high power field (HPF, 40x), with no lymphoid follicular aggregates and normal mucosal epithelium. 1 : mild gastritis; 10-50 inflammatory cells per HPF, fewer than two lymphoid follicular aggregates per low power field (LPF, 4x) and normal mucosal epithelium. 2 : moderate gastritis; 10-50 or more inflammatory cells per HPF, with greater than two lymphoid follicles per LPF and mild gastric epithelial changes. 3 : severe gastritis; greater than 50 inflammatory cells per HPF, with higher than two lymphoid follicles per LPF and marked gastric epithelial changes (Laurence et al., 1995).

Immunohistochemistry

Tissue sections on 3-aminopropylene-coated slides were used for immunohistochemistry. Sections were deparaffinized, rehydrated by immersion in xylene, graded alcohols and distilled de-ionized water and placed in a phosphate buffer saline solution (PBS). Endogenous peroxidase activity was blocked using 0.3% hydrogen peroxide at room temperature for 30 minutes (min), washing with PBS for 15 min and incubating with 10% skimmed milk for 20 min to block non-specific reactions. Sections were incubated with rabbit polyclonal anti-*Helicobacter pylori* antibody (DAKO, Denmark) in PBS at 4°C overnight. After another rinse in the PBS buffer solution, sections were consecutively incubated with peroxidase conjugated secondary antibody polymer (Nichirei, Japan) at 37°C for 30 min. The sections were developed to show a brown color, in 3-amino-9-benzidine tetrahydrochloride (DAB) solution, for 1-2 min and counterstained with Harris hematoxylin. Sections were dehydrated, mounted with permount and observed by microscopy. Tissues of stomach from *Helicobacter spp.*

infected dogs and normal gastric mucosa of piglets were used as positive and negative controls respectively.

Statistics

Data were analyzed by a non-parametric method. Cochran-mantel-Haenszel statistic was used for comparison to the gastritis score.

Results

The histopathological changes of pars esophagia were characterized by varying degrees of damage in the stratified squamous epithelium. The lesions included

mucosal thickness 54.78% (63/115), elongation of papillae 68.69% (79/115), parakeratosis 54.78% (63/115), vacuolated degeneration of the epithelium 83.47% (96/115), lymphoid follicular formation 74.78% (86/115), mononuclear inflammatory cells infiltration (44/115) and neovascularized granulation tissue in the lamina propria (12/115) (Fig. 1A). The histopathological changes of the pars esophagia between *Helicobacter spp.*, positive (+Ve) group and *Helicobacter spp.*, negative (-Ve) group were not significantly different (table 1). The histopathological changes of the glandular region consisted mainly of multifocal lymphoplasmacytic follicular aggregated in

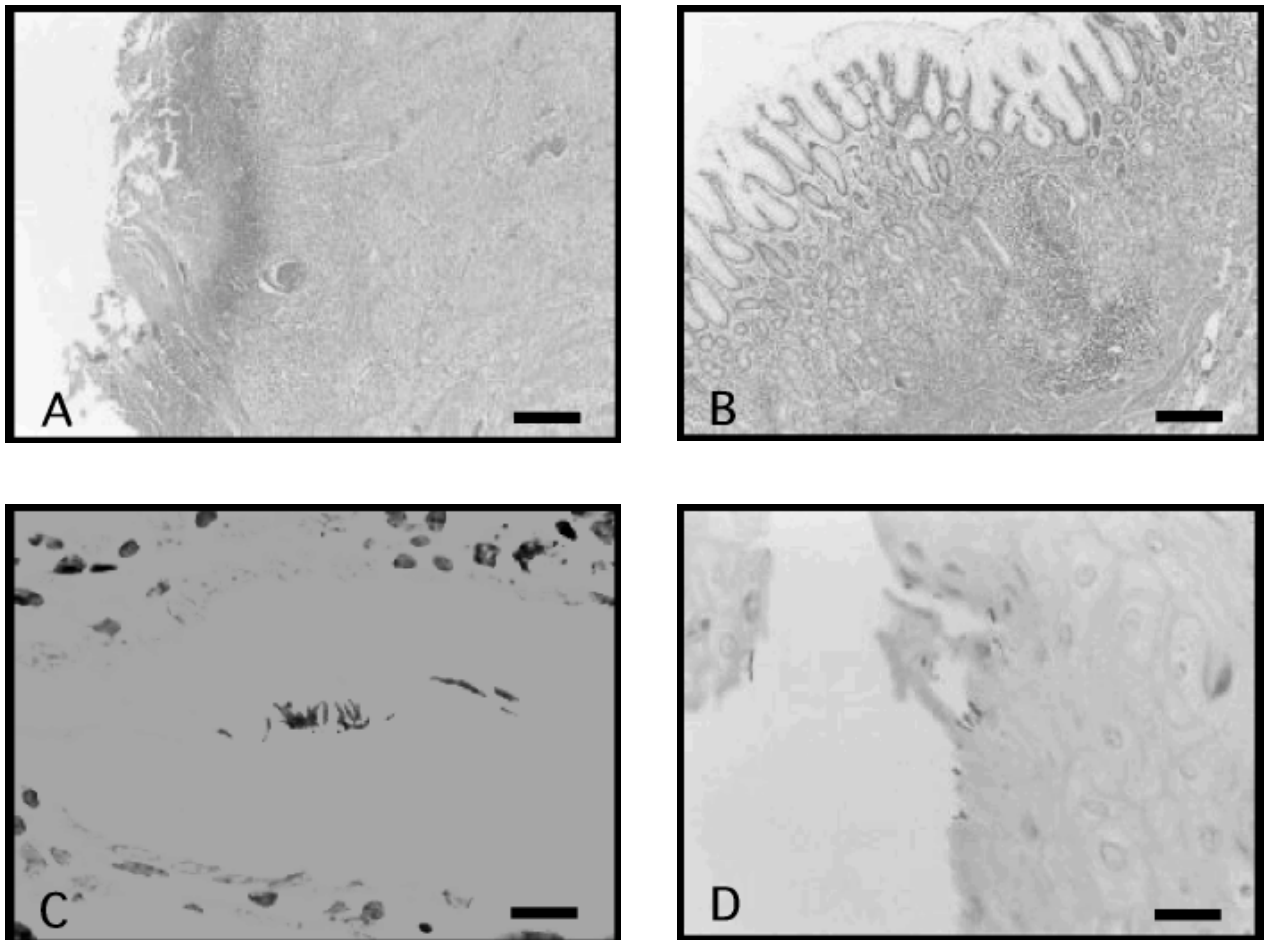


Figure 1 (A) : Typical lesions of epithelial necrosis with clumped bacteria of pars esophagia (H&E) (bar = 100 µm)
 (B) : Mucosal lymphoid follicle in the fundus (H&E) (bar = 100 µm)
 (C) : Numerous brownish-black spiral shaped bacteria distributed in the gastric pits of the fundus (Warthin starry) (bar = 100 µm)
 (D) : Immunohistochemical reaction of *Helicobacter spp.* in the epithelial lining of the pars esophagia (bar = 20 µm)

deep mucosa (Fig. 1B). The larger follicles displaced the gastric glands as they approached the superficial mucosa. Lymphoid follicles with prominent germinal centers were found in the lamina propria and the submucosal area of the fundus (88.69%), body (53.91%) and pyloric antrum (46.08%). Mucosal crypt distortion was detected in the fundus 42.60% (49/115), the body 7.82% (9/115) and the pyloric antrum 6.95% (8/115) respectively. Inflammatory cell infiltrations were mainly composed of mononuclear lymphocytes in the lamina propria and the submucosa of the fundus 88.69% (102/115), the body 31.30% (36/115) and the pyloric antrum 51.30% (59/115). The mean histopathological score of the glandular region was relatively high in fundus and was slightly seen in body and pyloric antrum. However, there was no difference in the mean histopathological score of the glandular regions between the *Helicobacter* positive group and the *Helicobacter* negative group (table 2).

The presence of *Helicobacter spp.* in pig stomachs using WS and immunohistochemical investigation revealed positive reaction 16.52% (19/115) and 13.91% (16/115) respectively. Bacteria were in situ demonstrated on the border surface of the epithelial lining 81.25% (13/16), in the lumen of the gastric glands 18.75% (3/16) and the gastric pits 25% (4/16) respectively (Fig 1C). For WS stain, Spiral bacteria were detectable in cardiac region 84.21% (16/19), fundus 26.32% (5/19), body 10.53% (2/19) and pyloric antrum 26.32% (5/19). For immunohistochemical study, *Helicobacter spp.* were mostly seen in the pars esophageal area 81.25% (13/16), the fundus 25% (4/16), and the pyloric antrum 18.75% (3/16) (Fig. 1D). No positive immunohistochemical reaction could be detected in the body of stomach.

Table 1 Histopathological changes of the pars esophagia

Histopathological change of the cardia	<i>Helicobacter</i> (+ve IHC)	<i>Helicobacter</i> (-ve IHC)
Increase mucosal thickness	8/16 (50%)	55/99 (55.56%)
Elongation of papillae	10/16 (62.50%)	69/99 (69.70%)
Parakeratosis	8/16 (50%)	55/99 (55.56%)
Vacuolation epithelium	13/16 (81.25%)	83/99 (83.84%)
Inflammatory cell infiltration	9/16 (56.25%)	35/99 (35.35%)
Neovascularized granulation tissue	3/16 (18.75%)	9/99 (9.09%)

Table 2 Mean histopathological scores of the glandular region

Mean histopathological score	<i>Helicobacter</i> (+ve IHC)	<i>Helicobacter</i> (-ve IHC)
	(n=16)	(n=99)
Fundus	1.33	1.31
Body	0.31	0.51
Pyloric antrum	0.50	0.60

Discussion

The morphological characterization of spiral bacteria has been demonstrated in the stomachs of pigs by WS and immunohistochemistry. There was no correlation between the histopathological change and the presence of *Helicobacter spp.* on the gastric mucosa. The prevalence of gastric ulcers in swine is greater than peptic ulcers in humans and it localizes mainly in the pars esophagia of stomach. In humans, it usually occurs in a small portion and is more frequently localized in duodenum and in the gastric antrum (Queiroz et al., 1996). The ulcer of the pars esophagia of swine presents several stage of evolution with the erosions probably originating from the desquamation of the epithelium as a result of parakeratotic alterations and with the ulcers representing advanced erosive lesions (Queiroz et al., 1996). Superficial changes restricted to the epithelium of pars esophagia such as parakeratosis, increased epithelium thickness or vacuolation of epithelial cell were observed with or without bacterial localization. This finding indicated an initial stage of the disease.

The histopathological responses of gastritis associated with *Helicobacter spp.*, in pigs predominantly consisted of mononuclear inflammatory cell infiltrates and contrasted with the chronic active gastritis associated with *Helicobacter spp.*, in humans (Roosendaal et al., 2000). Thus it indicates that different hosts present different histopathological responses to the different *Helicobacter spp.*

There have been great variations in the prevalence and severity of gastric ulcers. Abattoir surveys of the prevalence showed a range of 5 to 100% with an average of 63.2% for the 13 studies in different countries (Choi et al., 2001). The prevalence of *Helicobacter spp.* in the present study was relatively low when compared with other investigations (Cantet et al., 1999; Queiroz et al.,

1996; Roosendaal et al., 2000). Several factors influenced the prevalence rate of infection in pigs, such as type of breed, geographical zone, stress conditions, co-infection with other organisms or even the sensitivity of such detection methods (Mendes et al., 1991; Suarez et al., 1997). Moreover, overuse of antibiotics for bacterial control and treatment is widely practised in the industrial pig farms in Thailand which interfered with the bacterial localization in stomach. Based on immunohistochemical study, *Helicobacter spp.* was not distributed uniformly throughout the stomach because no positive reaction was observed in the body part of stomach. It was mainly located on the mucosal surface of the epithelial lining of pig stomach, especially the non-glandular part of cardiac region. According to Queiros and colleagues (1990), the spiral bacteria were seen in the mucus of the lumen of the antral pits and in the mucosal surface within and beneath the mucus of pig stomach.

In the present study, epithelial metaplasia in the stomach despite moderate gastritis could not be found, different from Chronic *H. pylori* infections in cats that develop mucosal atrophy, dysplasia and intestinal metaplasia in the stomach (Peterson et al., 2001). This may be attributed to differences in mucosal epithelial physiology and among the *Helicobacter* species. Furthermore, intestinal gastric metaplasia is a non specific response to mucosal injury by irritation, as are other environmental factors.

Altogether data, the study demonstrated the colonization of *Helicobacter spp.* in pig stomachs in Thailand, especially along the epithelial lining of cardiac region. There was no relationship between the gastric inflammation and the presence of *Helicobacter spp.* Unlike gastric ulcers associated with *H. pylori* in humans, the altered histopathological change of surface epithelial

cells, the activity of bacterial enzymes, including lipase, protease, urease and cytotoxin which causes vacuolation may result in cell injury and also apoptotic death of gastric mucosal epithelium (Esteves et al., 2000). The question arising whether this bacterium is the primary cause of gastric ulcers in pigs has remained controversial.

Acknowledgements

This work was supported by a grant from the Chulalongkorn University-Veterinary Science Research Fund 2002.

References

- Cantet, F., Magras, C., Marais, A., Federighi, M. and Graud, F. 1999. *Helicobacter* species colonizing pig stomach: Molecular characterization and determination of prevalence. *Applied Env. Microbiol.* 55(10): 4672-4676.
- Choi, Y.K., Han, J.H. and Joo, H. 2001. Identification of novel *Helicobacter* species in the pig stomach by PCR and partial sequencing. *J. Clin. Microbiol.* 39(9): 3311-3315.
- Doster, A.R. 2000. Porcine gastric ulcers. *Vet. Clin. North. Am. Food Anim. Pract.* 16(1): 163-174.
- Esteves, I.M., Schrenzel, D.M., Marini, R.P., Taylor, N.S., Xu, S., Hagen, S., Feng, Y., Shen, Z. and Fox, J.G. 2000. Animal model: *Helicobacter pylori* gastritis in cats with long-term natural infection as a model for human disease. *Am. J. Pathol.* 156: 709-721.
- Grasso, G.M., Ripabelli, G., Sammarco, M.L., Ruberto, A. and Iannitto, G. 1996. Prevalence of *Helicobacter*-like organisms in porcine gastric mucosa : a study of swine slaughtered in Italy. *Comp. Immun. Microbiol. Infect. Dis.* 19(3): 213-217.
- Groote, D.D., Ducatelle, R., van Doorn, L.J., Tilmant, K., Verschuuren, A. and Haesebrouck, F. 2000. Detection of "*Cadidatus Helicobacter suis*" in gastric samples of pigs by PCR: comparison with other invasive diagnostic techniques. *J. Clin. Microbiol.* 38(3): 1131-1135.
- Laurence, K.H., James G.F. and Harry, K. 1995. Characterization of feline *Helicobacter pylori* strains and associated gastritis in a colony of domestic cats. *J. Clin. Microbiol.* 33(9): 2280-2289.
- McGovern, K.J., Blanchard, T.G., Gutierrez, J.A., Czinn, J.S., Krakowka, S. and Youngman, P. 2001. β -Glutamyltransferase is a *Helicobacter pylori* virulent factor but is not essential for colonization. *Infect. Immun.* 69(6): 4168-4173.
- Mendes, E.N., Queiroz, M.M.D., Rocha, G.A., Nogueira, A.M.M.F., Carvalho, A.C.T., Lage, AP. And Barbosa, A.J.A. 1991. Histopathological study of porcine gastric mucosa with and without a spiral bacterium ("*Gastrospirillum suis*"). *J. Med. Microbiol.* 35: 345-348.
- Nakamura, S., Yao, T., Aoyagi, K., Lida, M., Fujishima, M. and Tsuneyoshi, M. 1997. *Helicobacter pylori* and primary gastric lymphoma : a histopathological and immunohistochemical analysis of 273 patients. *Cancer.* 79(1): 3-11.
- Peterson, R.A., Danon, S.J. and Eaton, K.A. 2001. Comparison of gastritis and gastric epithelial proliferation in *Helicobacter heilmannii*-infected nude and BALB/c mice. *Vet. Pathol.* 38: 173-183.
- Queiroz, D.M.M., Rocha, G.A., Mendes, E.N., Lage, A.P., Carvalho, A.C.T. and Barbosa, A.J.A. 1990. A spiral microorganism in the stomach of pigs. *Vet. Microbiol.* 24 : 199-204.

- Queiroz, D.M.M., Rocha, G.A., Mendes, E.N., Moura, S.B., Oliveira, A.M.R. and Miranda, D. 1996. Association between *Helicobacter* and gastric ulcer disease of the pars esophagia in swine. *Gastroenterology*. 111(1): 19-27.
- Roosendaal, R., Vos, J.H., Roumen, T., van Vugt, R., Cattoli, G., Bart, A., Klaasen, H.L.B.M., Kuipers, E., Vandenbroucke-Grauls, C.M.J.E. and Kusters, J.G. 2000. Slaughter pigs are commonly infected by closely related but distinct gastric ulcerative lesion-inducing *Gastrospirilla*. *J. Clin. Microbiol.* 38(7): 2661-2664.
- Simpson, K.W. and Neiger, R. 2000. *Helicobacter* infection in dogs and cats : facts and fiction. *J. Vet. Intern. Med.* 14: 125-133.
- Suarez, D.L., Wesley, I.V. and Larson, D.J. 1997. Detection of *Arconobacter* species in gastric samples from swine. *Vet. Microbiol.* 57: 325-336.