

9-1-2005

What is Your Diagnosis?

Pranee Tuntivanich

Suwicha Chuthateph

Follow this and additional works at: <https://digital.car.chula.ac.th/tjvm>



Part of the [Veterinary Medicine Commons](#)

Recommended Citation

Tuntivanich, Pranee and Chuthateph, Suwicha (2005) "What is Your Diagnosis?," *The Thai Journal of Veterinary Medicine*: Vol. 35: Iss. 3, Article 10.

Available at: <https://digital.car.chula.ac.th/tjvm/vol35/iss3/10>

This Other is brought to you for free and open access by the Chulalongkorn Journal Online (CUJO) at Chula Digital Collections. It has been accepted for inclusion in The Thai Journal of Veterinary Medicine by an authorized editor of Chula Digital Collections. For more information, please contact ChulaDC@car.chula.ac.th.

WHAT IS YOUR DIAGNOSIS

Pranee Tuntivanich Suwicha Chuthatep

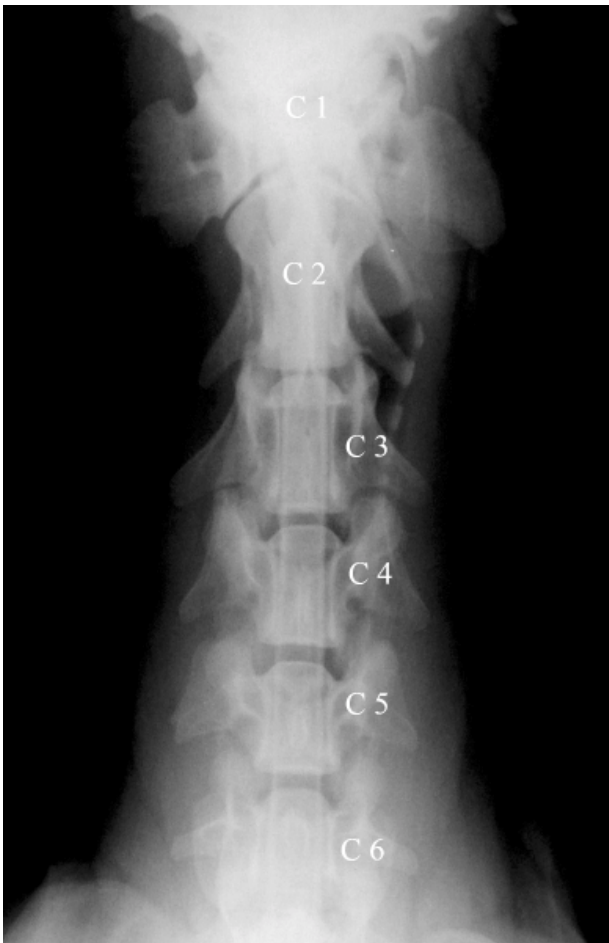

Figure 1 The ventrodorsal myelogram of the cervical spine

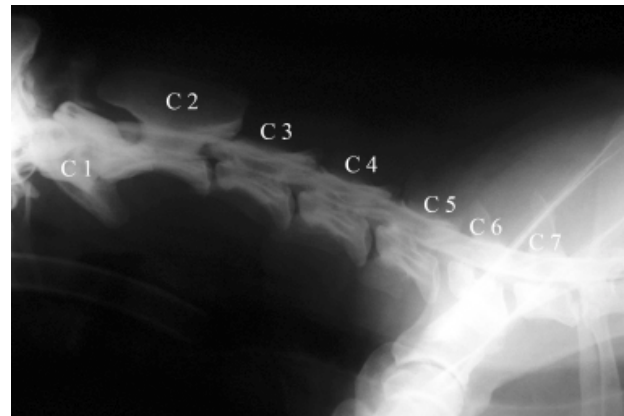


Figure 2 The lateral myelogram of the cervical spine

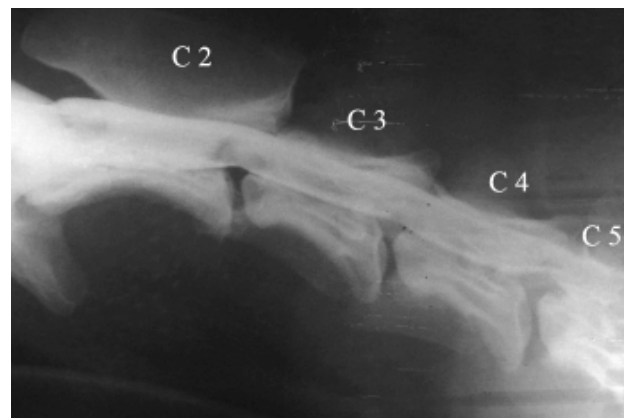


Figure 3 A magnified lateral myelogram of the cervical spine

History :

A 3 year-old Labrador Retriever was presented with initially both hindlimbs ataxic followed by revealed tetraparesis. A neurological examination revealed upper motor neuron signs with positive deep and superficial pain reflexes, a negative proprioceptive reflex, a wobbling head and extreme pain when the neck was flexed.

After no abnormalities was not detected in the plain survey radiographs, myelographic studies, including a ventrodorsal myelogram (Fig. 1) and lateral myelograms (Fig.2 and 3) of the cervical spine were performed.

Give your diagnosis and turn to the next page.

Radiographic Diagnosis

Caudal Cervical Spondylomyelopathy (Wobbler's Syndrome) at the C4-C5

Radiographic Findings and Comments

The ventrodorsal myelogram of the cervical spine (Fig.1) shows normal subarachnoid filling along the cervical region. The lateral myelograms (Fig.2 and 3) reveal an extradural lesion and dorsal deviation of the ventral, subarachnoid, contrast medium column, at the C4-C5. This cervical spine compression, caused by cervical, vertebral, malformation-malarticulation or instability, can be called Wobbler's Syndrome or caudal, cervical spondylomyelopathy. The cause of the skeletal malformation or malarticulation is unknown. Clinical studies suggest both genetics and nutrition may play a role in the development of such defects.

Diagnosis of Wobbler's Syndrome requires more extensive evaluation than plain survey radiographs can provide. A myelogram is used to confirm not only the location of the compression but also the amount of spinal cord swelling. Myelograms are a common and safe diagnostic procedures when performed with care and under proper conditions. Laboratory tests on blood and cerebrospinal fluid are usually within normal limits.

After the first clinical episode, treatment is directed primarily at the spinal cord injury by corticosteroid administration, to reduce any edema that may be present in the compressed segment of the spinal cord. However, medical therapy usually provides only temporary improvement. Surgery should be performed to provide spinal cord decompression, to remove any ruptured disc material and to repair some of the vertebral abnormalities together with stabilization.