

The Thai Journal of Veterinary Medicine

Volume 35
Issue 3 September, 2005

Article 8

9-1-2005

ECG Quiz

Chollada Buranakarl

Kris Angkanaporn

Follow this and additional works at: <https://digital.car.chula.ac.th/tjvm>



Part of the [Veterinary Medicine Commons](#)

Recommended Citation

Buranakarl, Chollada and Angkanaporn, Kris (2005) "ECG Quiz," *The Thai Journal of Veterinary Medicine*: Vol. 35: Iss. 3, Article 8.

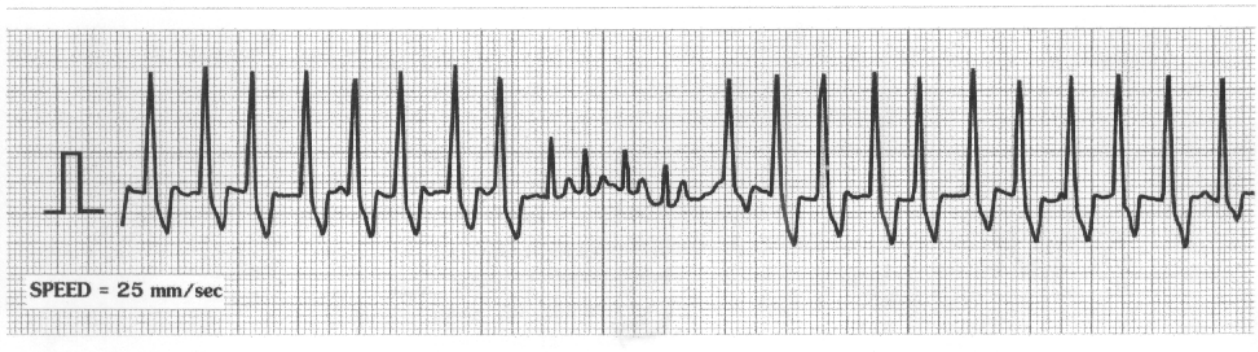DOI: <https://doi.org/10.56808/2985-1130.2016>

Available at: <https://digital.car.chula.ac.th/tjvm/vol35/iss3/8>

This Other is brought to you for free and open access by the Chulalongkorn Journal Online (CUJO) at Chula Digital Collections. It has been accepted for inclusion in The Thai Journal of Veterinary Medicine by an authorized editor of Chula Digital Collections. For more information, please contact ChulaDC@car.chula.ac.th.

ECG Quiz

Chollada Buranakarl* Kris Angkanaporn*

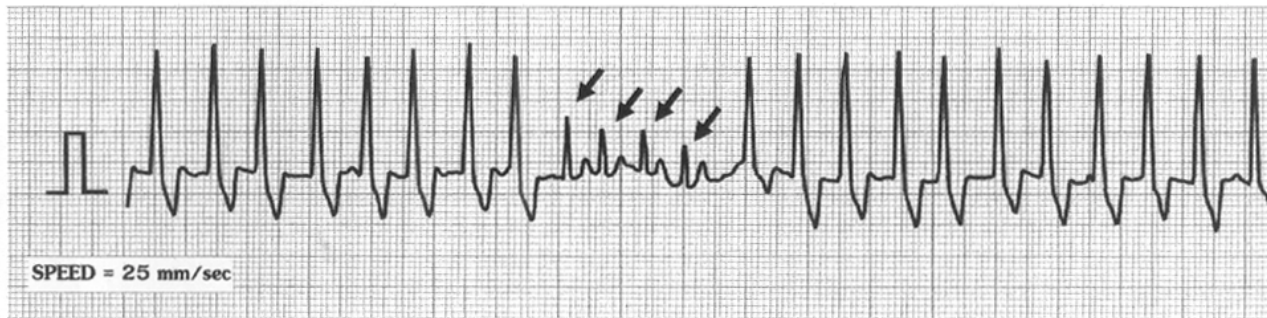


This complex lead II strip was recorded from a 14 year-old, male Cocker Spaniel weighing 15 kg, which had been admitted to the emergency unit of the small animal hospital, with a history of panting and restlessness. A physical examination revealed cyanotic membrane, normal hydration and an enlarged proximal part of the abdomen. Auscultation of the chest found heart arrhythmia

and a crackled lung sound. Blood and serum tests revealed a normal picture. The dog was diagnosed to have a gastric dilatation-volvulus (GDV) which was corrected by surgical procedures.

Please make your interpretation before turning to the next page.

Non-paroxysmal accelerating nonsustained ventricular tachycardia



The lead II strip shows normal sinus complexes in the middle of the strip (arrows) with multiple ventricular ectopic beats at the beginning and the end. The ectopic beats originated from the ventricle since the shape was bizarre and showed a prolonged QRS duration. An accelerating, nonsustained, ventricular tachycardia is a brief (fewer than 30 seconds) period of ventricular depolarization, during which the ventricular rate is increasing. The ectopic QRSs emerged when the sinus rate slowed down. When the sinus accelerates, it overdrives the ectopic pacemaker. Since the rate of ectopic beats was approximately 180 beats/minute which was slightly less than rate of the sinus beats (230 beats/minute) the paroxysmal ventricular tachycardia was not involved. This type of arrhythmia maybe caused by hemodynamic and electrical instability rather than the slow ventricular

rate. If the heart rate exceeds 170 beats/minute, passive ventricular filling is ordinarily not compromised, unless independently, ventricular function is severely depressed. It is commonly seen in dogs with splenic tumors, gastric dilatation-volvulus (GDV) or after trauma. In this case, the dog was confirmed to have GDV and the GDV was corrected by surgery. The cause was not a primary heart disease and the survival of these patients depends on skillful and timely medical and surgical attention to the primary cause and not antiarrhythmic drug therapy. In a large retrospective study of GDV dogs, antiarrhythmic drug therapy did not improve survival. By solving the primary problem, the arrhythmia can be resolved without treatment with an antiarrhythmic drug. This dog underwent surgery to correct GDV and became normal 10 days later.