

6-1-2005

## Ultrasound Diagnosis

Phiwipha Kamonrat

Follow this and additional works at: <https://digital.car.chula.ac.th/tjvm>



Part of the [Veterinary Medicine Commons](#)

---

### Recommended Citation

Kamonrat, Phiwipha (2005) "Ultrasound Diagnosis," *The Thai Journal of Veterinary Medicine*: Vol. 35: Iss. 2, Article 8.

Available at: <https://digital.car.chula.ac.th/tjvm/vol35/iss2/8>

This Other is brought to you for free and open access by the Chulalongkorn Journal Online (CUJO) at Chula Digital Collections. It has been accepted for inclusion in The Thai Journal of Veterinary Medicine by an authorized editor of Chula Digital Collections. For more information, please contact [ChulaDC@car.chula.ac.th](mailto:ChulaDC@car.chula.ac.th).

# ULTRASOUND DIAGNOSIS

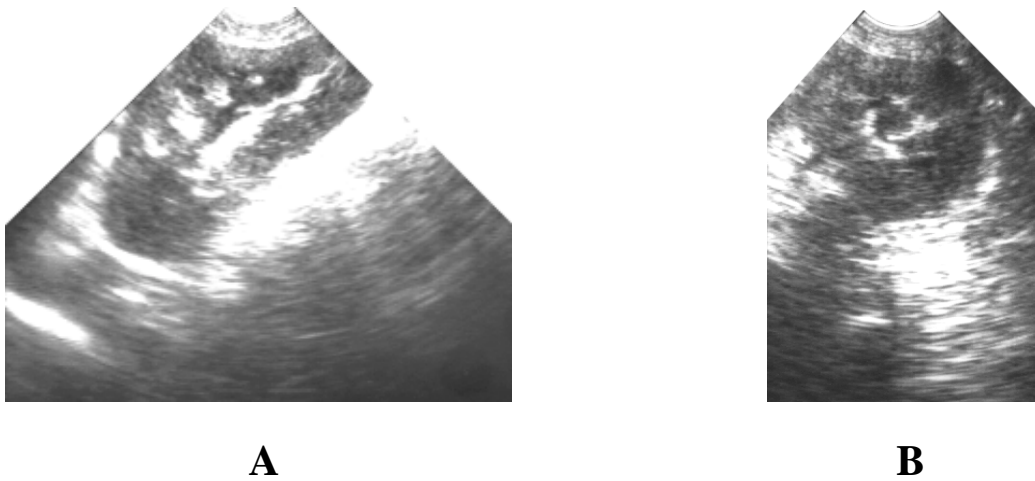
**Phiwipha Kamonrat**

## **History**

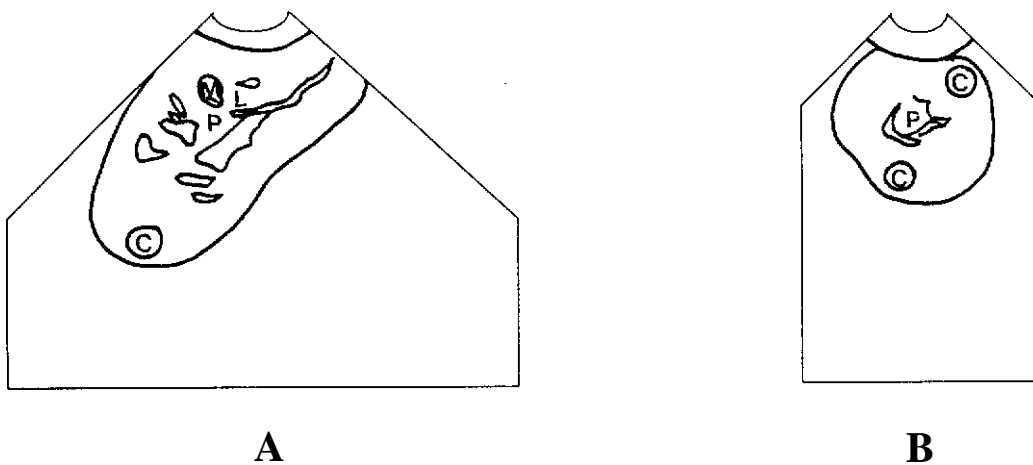
An eighteen-month-old, female Labrador dog was presented with a one-week history of depression, inappetance and vomiting. Physical examination revealed normal mucous membranes. The dog showed signs of slight pain in the renal area during abdominal palpation. Haematological examination revealed a marked leukocytosis, with a regenerative left shift (25,400 white blood cells/ $\mu$ l, 86% neutrophils, 3% band cells, 7% monocytes and 4% lymphocytes). Biochemical examination showed an elevated serum creatinine concentration (3.19 mg/dl). Urinalysis was unremarkable. Survey radiography demonstrated enlargement of both kidneys. An abdominal ultrasonography was performed to obtain more specific information.

## **Ultrasonographic Findings**

Trans-abdominal ultrasonography evaluation of the abdomen was performed using an electronic, sector, real-time scanner of 5 MHz frequency. On longitudinal (Figure 1A and 2A) and transverse (Figure 1B and 2B) scans of both kidneys, the renal cortex appeared normally hypoechoic compared to the liver and the spleen. Both kidneys were enlarged, especially the left one (the diameter of left and right kidneys was 5.5 x 9.9 x 5.8 and 5.1 x 8.6 x 5.7 cm, respectively). There was a mild dilatation of the renal pelvis and a hyperechoic line within the renal pelvis. Hyperechoic and hypoechoic foci were apparent within the medullary tissue and the renal cortex, respectively. The urinary bladder was seen to be markedly distended with clear anechoic urine. The urinary bladder wall was smooth, echoic, and 1.3 mm thick. Other findings were within normal limits.



**Figure 1** Sagittal (A) and transverse (B) ultrasonographic images of the left kidney of a 18-month-old, female, Labrador, in dorsal recumbency. A hyperechoic line can be seen within the dilated renal pelvis. Hyperechoic and hypoechoic foci are seen within the medullary tissue and the renal cortex, respectively.



**Figure 2** Schematics of the relative positions of the structures scanned in figure 1. P -anechoic renal pelvis; L -hyperechoic line within renal pelvis; M -hyperechoic focus within the renal medulla; C -hypoechoic focus within the renal cortex.

## Diagnosis

Ultrasonographic diagnosis—acute pyelonephritis.

## Comments

Renal pelvic dilation is ultrasonographically recognized by an anechoic space, separating it from the normal, uniformly hyperechoic central renal sinus. It can usually be seen surrounding the renal crest in the transverse plane. Mild pelvic dilation can be seen during diuresis in normal animals, but it is considered abnormal if the dilation is more than 3-4 mm. The amount of dilation seen with pyelonephritis is not as extensive as that in hydronephrosis. Nephrosonography appears to be useful for the detection of mild to moderate cases of acute pyelonephritis. A sonographic diagnosis of pyelonephritis is defined as any combination of two or more of the

following: dilatation of the proximal ureter or the renal pelvis, presence of a hyperechoic mucosal margin line, parallel to the wall of the pelvis or proximal ureter, focal hyperechoic areas in the renal medulla, hypoechoic or hyperechoic foci within the renal cortex, poor corticomedullary differentiation, and a proximal ureter measuring greater than 0.18 cm in diameter.

Nephrosonography is easy to perform, the equipment is widely available and requires minimal patient preparation. It is used to define the renal anatomy and the extent of the disease. Although the ultrasonographic patterns associated with diffuse infiltrative parenchymal disease, without architectural disruption, are nonspecific, it does help in narrowing the spectrum of information, not obtainable by survey radiography and excretory urography.