

# The Thai Journal of Veterinary Medicine

---

Volume 34  
Issue 2 June, 2004

Article 10

---

6-1-2004

## ECG Quiz

Chollada Buranakarl

Kris Angkanaporn

Follow this and additional works at: <https://digital.car.chula.ac.th/tjvm>



Part of the [Veterinary Medicine Commons](#)

---

### Recommended Citation

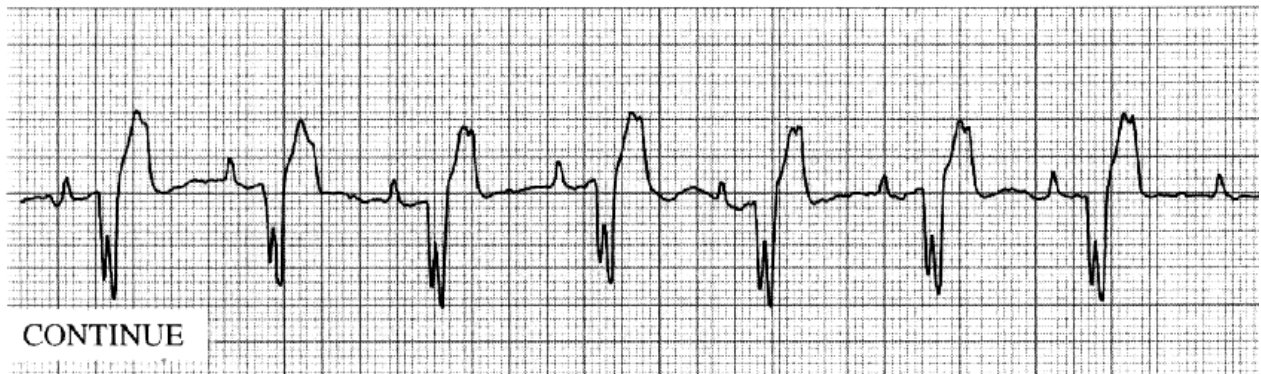
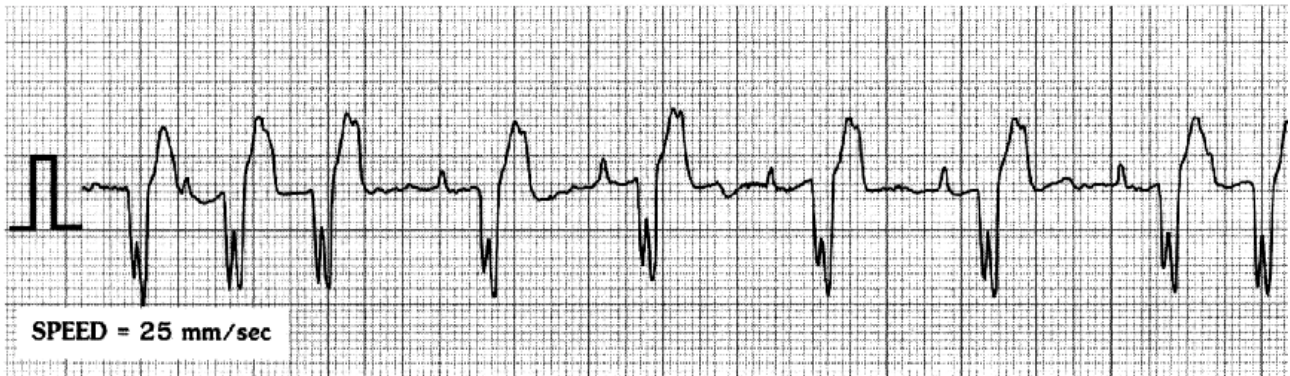
Buranakarl, Chollada and Angkanaporn, Kris (2004) "ECG Quiz," *The Thai Journal of Veterinary Medicine*: Vol. 34: Iss. 2, Article 10.

Available at: <https://digital.car.chula.ac.th/tjvm/vol34/iss2/10>

This Other is brought to you for free and open access by the Chulalongkorn Journal Online (CUJO) at Chula Digital Collections. It has been accepted for inclusion in The Thai Journal of Veterinary Medicine by an authorized editor of Chula Digital Collections. For more information, please contact [ChulaDC@car.chula.ac.th](mailto:ChulaDC@car.chula.ac.th).

## ECG Quiz

Chollada Buranakarl\* Kris Angkanaporn



The complex lead II strip was recorded from an 11 year-old male Thai dog, weighing 21.8 kg, with a history of lethargy, productive cough, exercise intolerance and panting. A physical examination revealed pale mucous membranes, dehydration, with fluid in the abdomen.

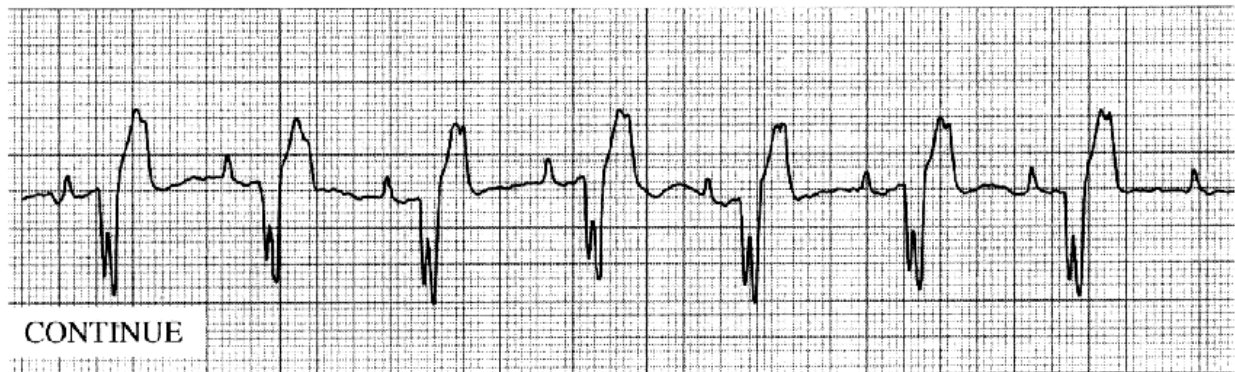
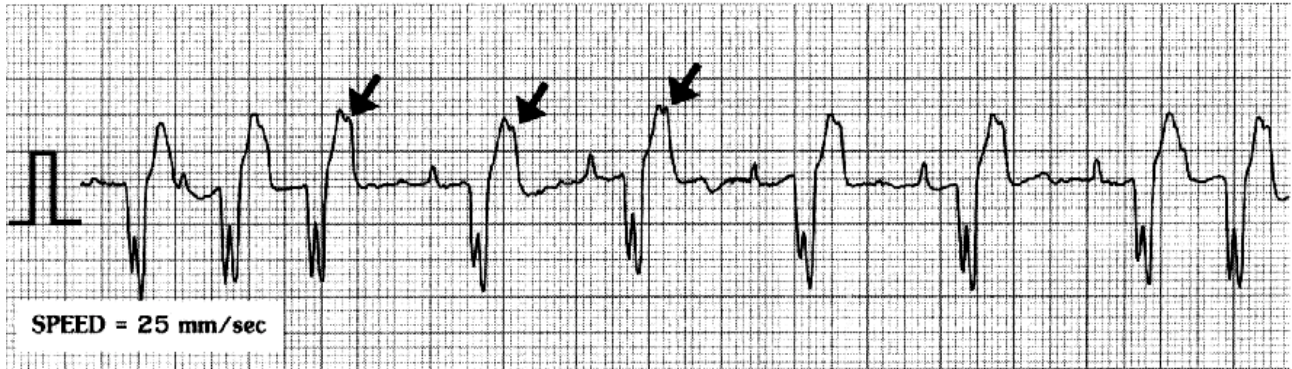
The thoracic radiograph revealed a marked enlargement of the whole heart and interstitial and alveolar patterns in all lung lobes. An abdominal radiograph showed a ground glass appearance.

P wave amplitude	=	0.4 mV
P wave duration	=	0.06 sec
QS duration	=	0.12 sec
PR interval	=	0.24 sec
Mean electrical axis	=	+115°

Please make your interpretation before turning to the next page

## Interpretation

### Sinus rhythm with second degree atrioventricular (AV) block and right bundle branch block (RBBB)



The ventricular rate is approximately 71 beats per minute, while the atrial rate is 132 beats per minute. We can see the normal P wave followed by a bizarre QS wave with a notch. No positive R wave can be seen. The positive T-wave, following the QS wave, also had slur, due to the superimposed non-conduct P wave (arrow). In the first strip, the first three complexes originated from the sinus pacemaker as impulses can transmit from the atrium and the ventricle. The 4<sup>th</sup> P wave cannot pass through the AV node so there is a period of pause. The next sequence is present with 2:1 of P and QS complexes, suggesting a second degree AV block. The AV block was terminated at the end of the first strip. In strip II, a regular 2:1, second degree, AV block was seen. A second degree AV block can be confused with complete AV dissociation and ventricular arrhythmia. However, they can be

eliminated by the consistent PR interval, suggesting that the QRS waves followed the preceding P waves. In both cases, there is no relationship between P waves and the QRS complexes. Moreover, the deep and wide QS wave with a consistent PR interval and right axis deviation, is typical for a right bundle-branch block. Lead I, III and AVF also have wide and deep S waves. In this case whole heart enlargement can be seen from the thoracic radiograph and a congestive biventricular failure was diagnosed. Heartworm disease needs to be ruled out and heart function further evaluated with echocardiography. AV block will be a more detrimental situation more RBBB. The treatment that is required with vasodilators and diuretics. Digoxin may be necessary while the ventricular rate and the degree of AV block is monitored.