

# The Thai Journal of Veterinary Medicine

---

Volume 33  
Issue 4 December, 2003

Article 2

---

12-1-2003

## ECG Quiz

Chollada Buranakarl

Kris Angkanaporn

Suwanakiet Sawangkoon

Follow this and additional works at: <https://digital.car.chula.ac.th/tjvm>



Part of the [Veterinary Medicine Commons](#)

---

### Recommended Citation

Buranakarl, Chollada; Angkanaporn, Kris; and Sawangkoon, Suwanakiet (2003) "ECG Quiz," *The Thai Journal of Veterinary Medicine*: Vol. 33: Iss. 4, Article 2.

Available at: <https://digital.car.chula.ac.th/tjvm/vol33/iss4/2>

This Other is brought to you for free and open access by the Chulalongkorn Journal Online (CUJO) at Chula Digital Collections. It has been accepted for inclusion in The Thai Journal of Veterinary Medicine by an authorized editor of Chula Digital Collections. For more information, please contact [ChulaDC@car.chula.ac.th](mailto:ChulaDC@car.chula.ac.th).

## ECG Quiz

Chollada Buranakarl\* Kris Angkanaporn\* Suwanakiat Sawangkoon\*

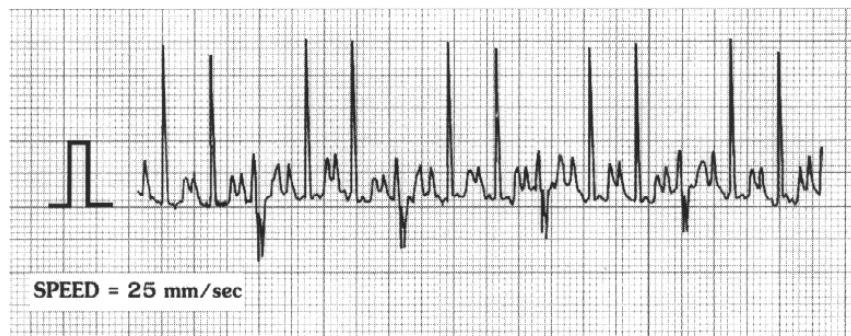


Fig 1a Before treatment

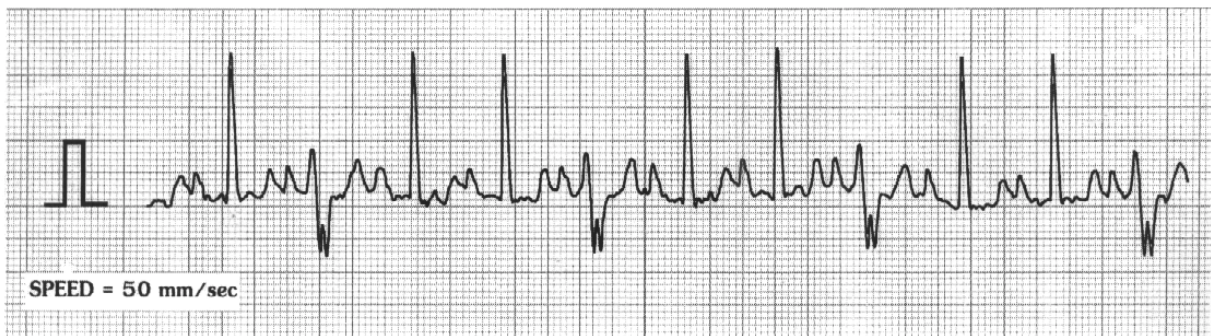


Fig 1b Before treatment (followed 1a with different paper speed)

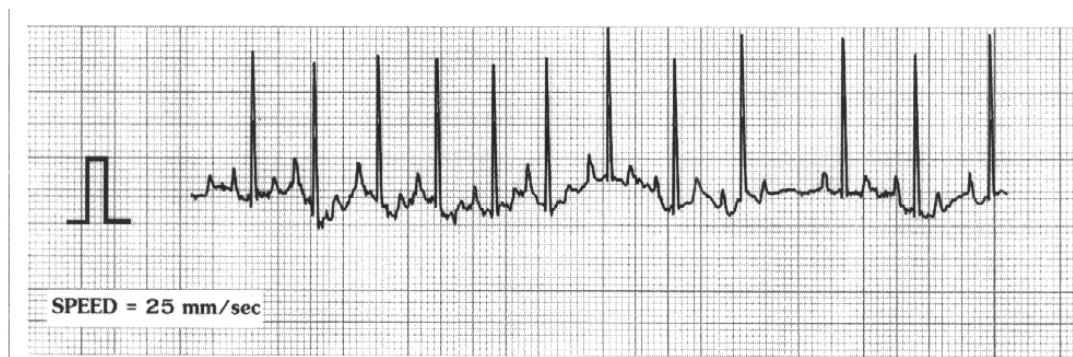


Fig 2 After treatment

---

\*Department of Physiology, Faculty of Veterinary Science, Chulalongkorn University, Pathumwan, Bangkok 10330.

\*Corresponding author

A nine-year old, male, Basset Hound was hospitalized with signs of anorexia, syncope, dyspnea, vomiting, showing blood stained coughing and depression. A thoracic radiograph revealed whole heart enlargement with interstitial and bronchial patterns prominent in the lung. A complete blood count showed an increased red blood cell count ( $9.2 \times 10^6$  cell/ $\mu$ l) and slight leukocytosis (WBC = 18,500 cell/ $\mu$ l). Blood chemistry profiles for liver and kidney function were within normal limits.

P wave duration	=	0.08	sec
P wave amplitude	=	0.4	mV
PR interval	=	0.12	sec
R wave amplitude	=	2.3	mV
QRS interval	=	0.04	sec
QT interval	=	0.18	sec
Mean E.ctrical Axis	=	+75°	

Please make your interpretation before turning to the next page.

### Sinus tachycardia with periodic aberrant conduction causing fusion beat

In fig 1b, two sinus complexes were found with a wide P wave known as "P mitrale" (P duration > 0.16 sec.) (dark arrow). This characteristic may indicate left atrial enlargement which corresponded to the image seen in the thoracic radiograph. The heart rate was 200 bpm, indicating Sinus tachycardia (Fig 1a). After the duplicated sinus complexes, another complex followed with a bizarre negative deflection and a notch (open arrow). This feature was similar to a deep S wave with a long duration and a right bundle branch block (RBBB) was suspected. However, by measuring the PR duration of normal sinus waveforms, the peak of R wave fell on the location at the

peak of the notch of the bizarre wave. It is likely that this wave was a fusion beat of the normal sinus and the aberrant conduction was caused by ventricular ectopic beats or by reentry mechanism. Tachycardia and a dilated myocardium will accentuate myocardial function, leading to cardiac failure. The poor cardiac output, that accompanies a rapid heart rate, inadequate cardiac filling time and poor contractability may cause the syncope because of inadequate cerebral blood flow. After digoxin therapy, the aberrant conduction was eliminated and the heart rate slowed down (HR = 144 bpm) (Fig 2). The dogs condition improved and no syncope was found.

