

5-1-1980

## ปริศนาคสึนไฟฟ้าหัวใจ

ฉลาด โสมะบุตร

Follow this and additional works at: <https://digital.car.chula.ac.th/clmjournal>



Part of the [Medicine and Health Sciences Commons](#)

---

### Recommended Citation

โสมะบุตร, ฉลาด (1980) "ปริศนาคสึนไฟฟ้าหัวใจ," *Chulalongkorn Medical Journal*: Vol. 24: Iss. 3, Article 6.

DOI: <https://doi.org/10.58837/CHULA.CMJ.24.3.6>

Available at: <https://digital.car.chula.ac.th/clmjournal/vol24/iss3/6>

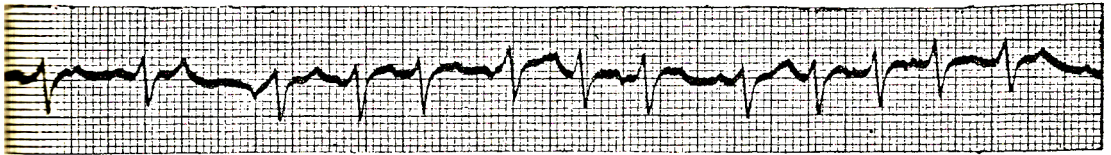
This Other is brought to you for free and open access by the Chulalongkorn Journal Online (CUJO) at Chula Digital Collections. It has been accepted for inclusion in Chulalongkorn Medical Journal by an authorized editor of Chula Digital Collections. For more information, please contact [ChulaDC@car.chula.ac.th](mailto:ChulaDC@car.chula.ac.th).

---

ยริศนาคสิ่น โฝข้้าห้วใจ

## ปรีศนาคลีนไฟฟ้าหัวใจ

ฉลาค โสฆบฏร์



A 60 years old male was hospitalized with palpitation and dyspnea.

What is your electrocardiographic diagnosis?

- A. Atrial fibrillation c rapid ventricular response
- B. Multifocal atrial tachycardia
- C. Second degree A-V block
- D. Ventricular tachycardia.

*Answer B*

The tracing showed rapid irregular rhythm  $\bar{c}$  narrow QRS complex. There appears to be multiforms P wave  $\bar{c}$  variable PR interval consistent with multifocal atrial pace maker. Since ventricular rate is more than 100/min the diagnosis should best be multifocal atrial tachycardia or so called chaotic atrial rhythm.