

3-1-2003

ECG Quiz

Chollada Buranakarl

Kris Angkanaporn

Sumpun Thammacharoen

Follow this and additional works at: <https://digital.car.chula.ac.th/tjvm>



Part of the [Veterinary Medicine Commons](#)

Recommended Citation

Buranakarl, Chollada; Angkanaporn, Kris; and Thammacharoen, Sumpun (2003) "ECG Quiz," *The Thai Journal of Veterinary Medicine*: Vol. 33: Iss. 1, Article 9.

Available at: <https://digital.car.chula.ac.th/tjvm/vol33/iss1/9>

This Other is brought to you for free and open access by the Chulalongkorn Journal Online (CUJO) at Chula Digital Collections. It has been accepted for inclusion in The Thai Journal of Veterinary Medicine by an authorized editor of Chula Digital Collections. For more information, please contact ChulaDC@car.chula.ac.th.

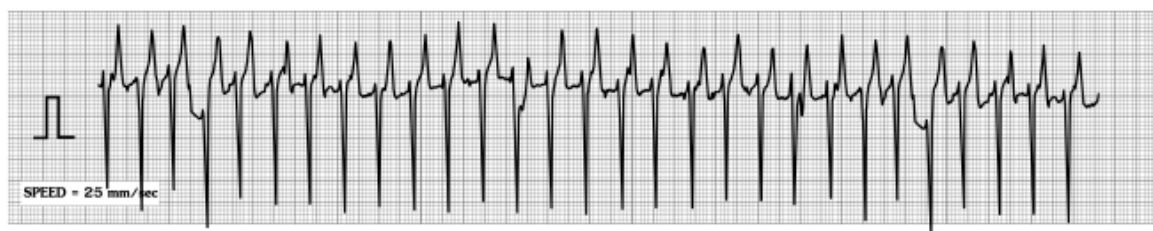
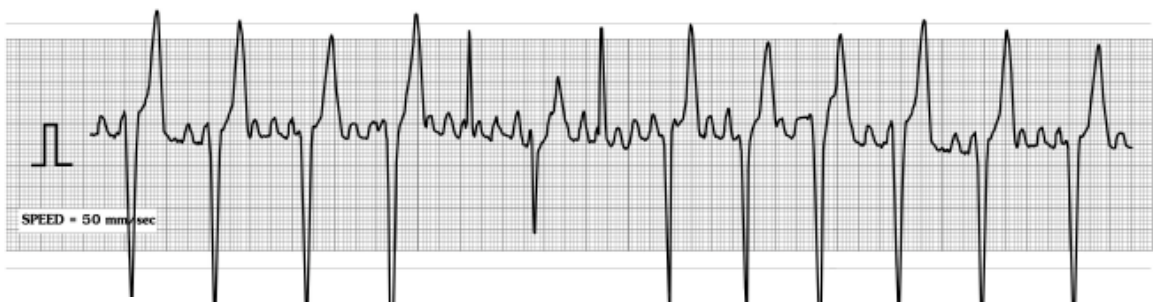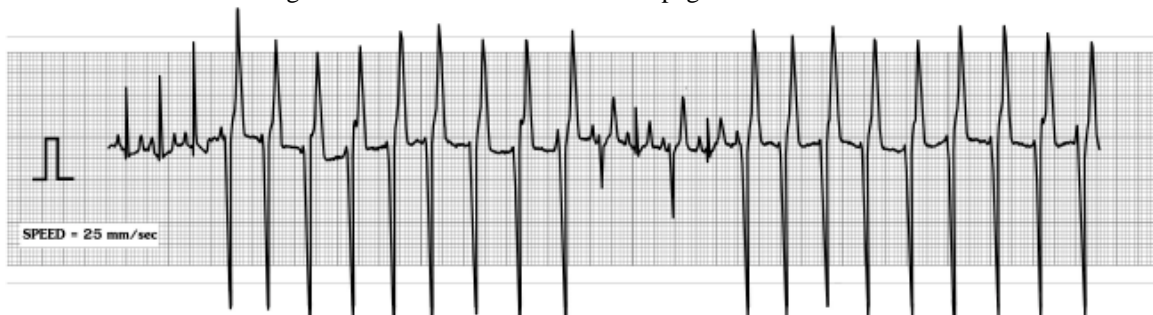ECG Quiz

Chollada Buranakarl* Kris Angkanaporn Sumpun Thammacharoen

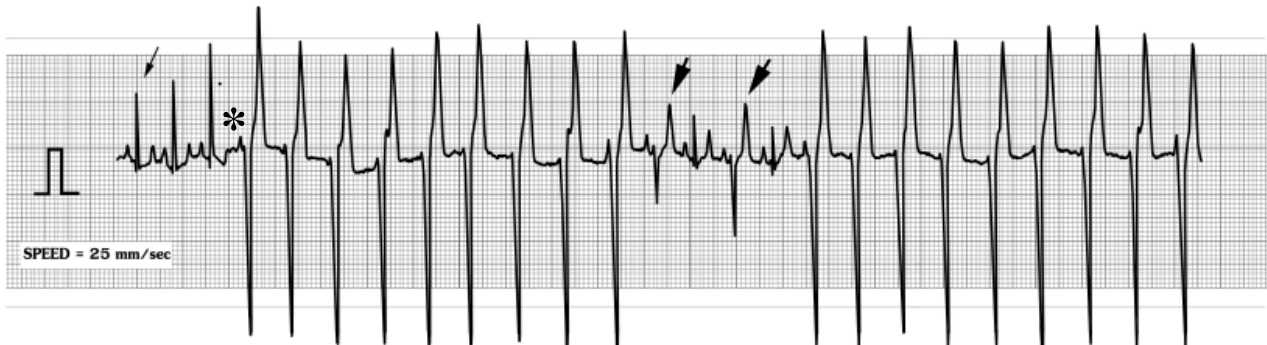Three lead II ECG strips were recorded from a 9 year-old female mixed breed dog, weighing 12.5 kg, with a history of weight loss (this dog used to have a normal weight of 20 kg, two years ago), anorexia and lethargy over the past 3 weeks. The owner took the dog to private clinic and a blood sample showed that animal was azotemic. Fluid was given for 3 weeks but the condition did not improved. After admission, blood was taken for a complete blood count and a biochemical profile. The number of red and white blood cells were within the normal range. The liver profile was normal while the concentration of blood urea nitrogen and creatinine in the

plasma were markedly elevated (140 mg% and 12.9 mg%, respectively). Five days after treatment, the dog had a seizure for 10 minutes and stopped breathing but she gained consciousness after the owner helped her by compressing the chest. Thoracic radiographs were performed the next day and a slight enlargement of right heart and an interstitial pattern in the lung lobes were found. The right kidney was also enlarged.

Please make your interpretation before turning to the next page.



Intermittent ventricular tachycardia (strip a repeated)



Sinus rate is 188 beats/minute. The sinus complexes were seen on the strip a of ECG (arrow). It was noted that the positive QRS complexes were found at the beginning of the tracing which suggest that the impulse was conducted via normal pathway. The height of QRS amplitude was variable, which may be due to either the electrical instability, with varying degree of conduction velocity, or body position shift during ECG recording. The ventricular ectopic focus was competed with the impulse from the sinus. Once the ectopic depolarizes and reaches the threshold, the ventricular ectopic rhythm will overdrive the sinus pacemaker. The P wave was present prior to ventricular ectopic rhythm but it cannot conduct through the normal conducting pathway (non-conduct

P wave;*). The ventricle keeps pacing at high rate independent of atrial contractions. On the strip b, we can see the multiple P waves which suggests that the atrial contraction was sometimes fast with unorganized conduction called atrial flutter. Sustained ventricular tachycardia occurred as long as P on T of ventricular ectopic beat continued. During transition stage, fusion beats were also seen, which can be seen by the QRS-T morphology displaying intermediate features between the sinus and ectopic beats (big arrow). On the strip c, the sustained ventricular tachycardia was seen which can produce low cardiac output leading to fatal result. The dog died a few days later and the autopsy was not performed to find out the cause of abnormal rhythm.