

12-12-2002

What is Your Diagnosis?

Pranee Tuntivanich

Follow this and additional works at: <https://digital.car.chula.ac.th/tjvm>



Part of the [Veterinary Medicine Commons](#)

Recommended Citation

Tuntivanich, Pranee (2002) "What is Your Diagnosis?," *The Thai Journal of Veterinary Medicine*: Vol. 32: Iss. 4, Article 12.

DOI: <https://doi.org/10.56808/2985-1130.1899>

Available at: <https://digital.car.chula.ac.th/tjvm/vol32/iss4/12>

This Other is brought to you for free and open access by the Chulalongkorn Journal Online (CUJO) at Chula Digital Collections. It has been accepted for inclusion in The Thai Journal of Veterinary Medicine by an authorized editor of Chula Digital Collections. For more information, please contact ChulaDC@car.chula.ac.th.

WHAT IS YOUR DIAGNOSIS

Pranee Tuntivanich

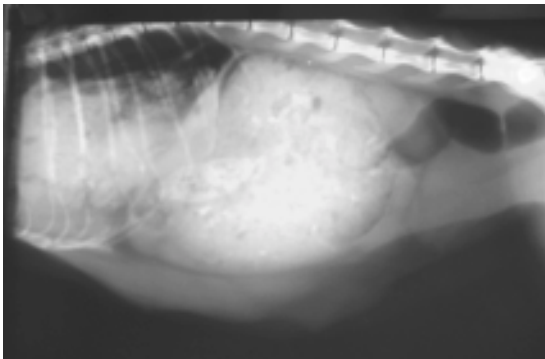


Figure 1 Lateral view of an abdomen of a cat.

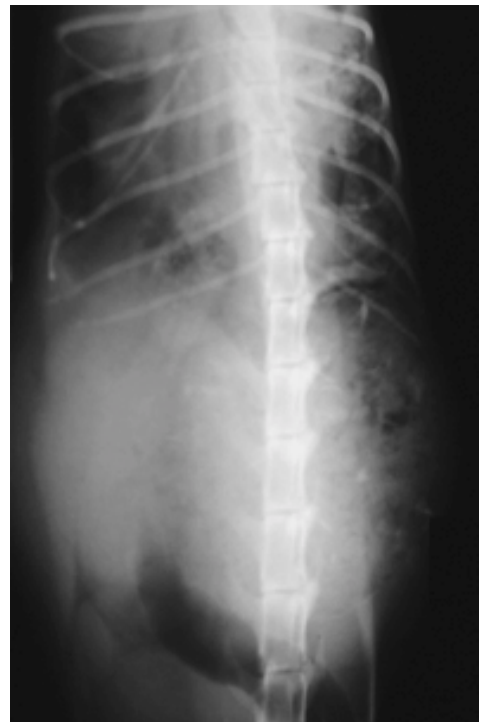

Figure 2 Ventro-dorsal view of an abdomen of the same cat.

History :

A two year old female mixed breed cat with symptoms of depression and panting when 2 months pregnant. No evidence of a vaginal discharge. The animal had a good appetite. Palpation revealed a mass in the abdominal cavity.

Radiographs of the abdomen both in the lateral and ventro-dorsal positions.

Give your diagnosis and turn to page 92.

Radiographic Diagnosis

Diaphragmatic hernia

Radiographic Findings and Comments

The lateral view of the abdomen revealed a stomach filled with ingesta and displaced posteriorly with the distal colon filled with gas. Some part of the intestine, filled with ingesta, can be seen in the thoracic cavity.

The ventro-dorsal view of the abdomen revealed an ingesta filled stomach on the left side of the abdomen displacing all the other abdominal

organs to the right side. Some part of the intestine, filled with feces, is protruding through the rupture on the left of the diaphragm into the thoracic cavity. Ruptures of the diaphragm do occur.

Most diaphragmatic hernias in dogs and cats are acquired and are traumatic in origin. Herniation of the bowel through a ruptured diaphragm can be detected radiographically. A diaphragmatic hernia results in increased bowel content and fluid within the thoracic cavity, producing compression of the lungs and dyspnea. A congenital diaphragmatic hernia can result from incomplete formation of the diaphragm.