

12-11-2002

## Ultrasound Diagnosis

Phiwipha Kamonrat

Follow this and additional works at: <https://digital.car.chula.ac.th/tjvm>



Part of the [Veterinary Medicine Commons](#)

---

### Recommended Citation

Kamonrat, Phiwipha (2002) "Ultrasound Diagnosis," *The Thai Journal of Veterinary Medicine*: Vol. 32: Iss. 4, Article 11.

DOI: <https://doi.org/10.56808/2985-1130.1898>

Available at: <https://digital.car.chula.ac.th/tjvm/vol32/iss4/11>

This Other is brought to you for free and open access by the Chulalongkorn Journal Online (CUJO) at Chula Digital Collections. It has been accepted for inclusion in The Thai Journal of Veterinary Medicine by an authorized editor of Chula Digital Collections. For more information, please contact [ChulaDC@car.chula.ac.th](mailto:ChulaDC@car.chula.ac.th).

# ULTRASOUND DIAGNOSIS

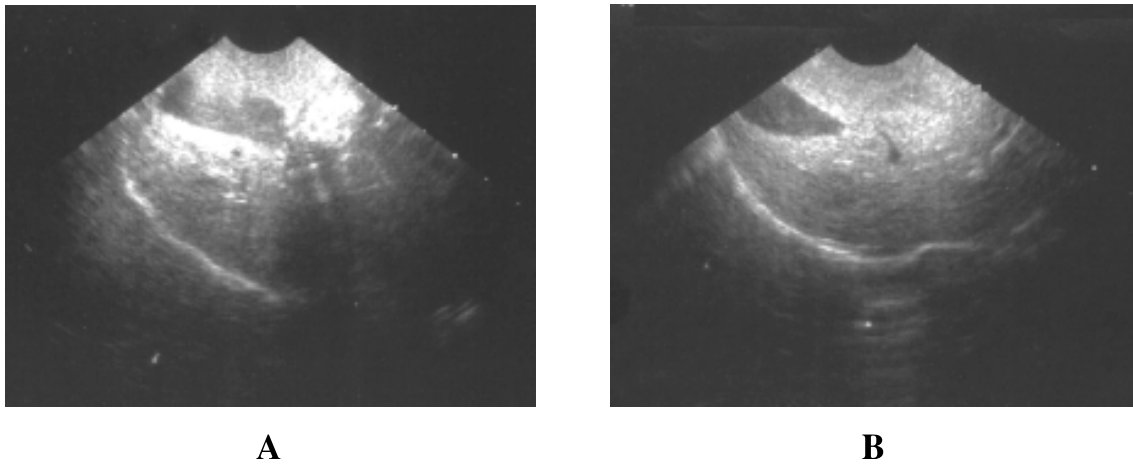
**Phiwipha Kamonrat**

## **History**

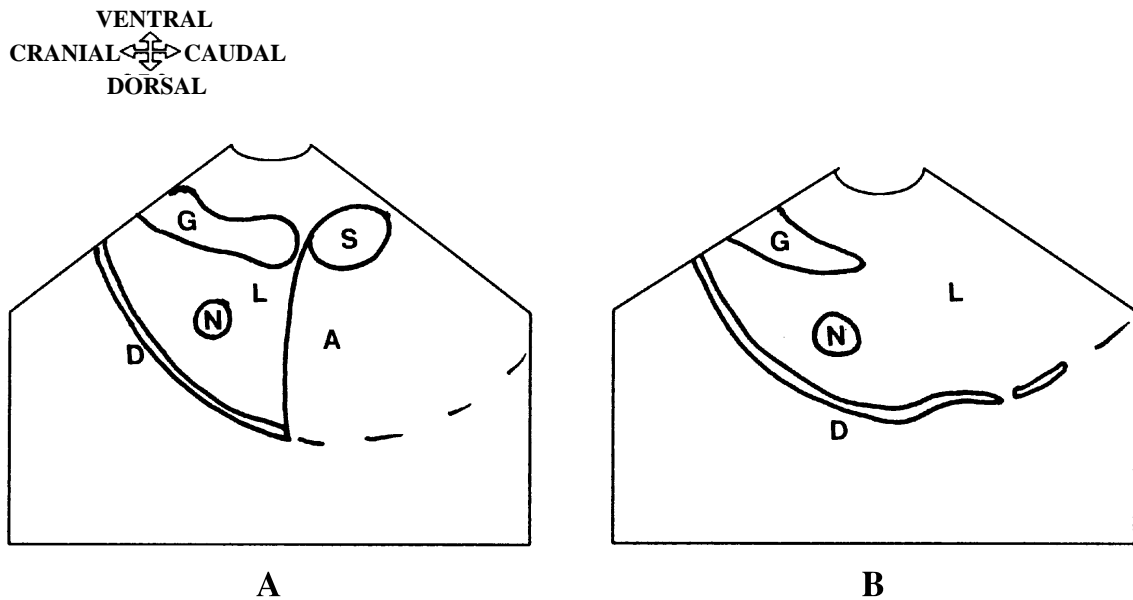
An eleven-year-old, spayed, Miniature dog was presented at the Chulalongkorn University, Small Animal, Veterinary Teaching Hospital with acute signs of vomiting. Physical examination revealed yellowish mucous membranes. A complete blood count and a serum biochemistry profile were performed. Abnormal clinical values included, marked elevation of Serum Alanine Aminotransferase (ALT) (1,300 units), Alkaline Phosphatase (ALP) (8,000 units), Cholesterol (1,138 mg%) and Triglyceride (293 mg%). Over a period of one month of treatment for liver disease, ALT had returned to the normal level of 28 units and ALP decreased to a near normal level (311 units). At the last visit, four months after the first presentation, the dog was healthy with a normal appetite and pink mucous membranes. Hematological and serum biochemistry profiles were within normal ranges with the exception of a mild elevation of ALP (239 units). Ultrasonography of the liver was performed and followed up every 1-2 months.

## **Ultrasonographic Findings**

Ultrasonographic examination of the abdomen was performed using a real time scanner with an 8-5 MHz broadband, convex, phased array transducer. The overall hepatic parenchyma was hyperechoic to the kidneys and hypoechoic to the spleen. Only one hypoechoic focal area, 1 by 1.2 cm in diameter, was detected in the right hepatic lobe (figures 1A and 2A). The size of this lesion was slightly changed on the follow-up studies, performed every 1-2 months, and measured 1 by 1.3 cm after four months (Figs 1B and 2B). Other lesions in adjacent abdominal organs were not found.



**Figure 1** Transhepatic ultrasonograms of an eleven-year-old, Miniature dog, in dorsal recumbency. A benign nodule with hypoechoic echogenicity, compared with surrounding hepatic parenchyma, was 1 x 1.2 cm at the first presentation (A) and 1 x 1.3 cm four months later (B).



**Figure 2** Schematics of the relative positions of the structures scanned in Figure 1. L-hepatic parenchyma; D-diaphragm; G-gall bladder; N-hypoechoic nodule; S-stomach; A-acoustic shadowing.

## Diagnosis

Ultrasonographic diagnosis —A benign hepatic nodule.

## Comments

Ultrasonography is a noninvasive, rapid means that is primarily used to detect parenchymal lesions, identify the required tissue samples, monitor the course of the disease and if therapy is initiated, predict the progression of the disease. An ultrasound-guided liver biopsy is mainly performed to rule out neoplasia since the cytologic and histologic appearances may be nondiagnostic or difficult to distinguish specifically (Nyland et al., 2002).

To avoid possible complications from a tissue-core biopsy technique (Barr, 1995) and at the

request of the dog's owner, ultrasonography was used to observing any aggressive characteristics of the lesion. The ultrasonographic features suggested that the hypoechoic lesion presented in this dog was a nonaggressive benign nodule, which includes hematomas, abscesses, necrosis, granulomas or nodular hyperplasia.

## References

- Barr F. 1995. Percutaneous biopsy of abdominal organs under ultrasound guidance. *J. Small Anim. Pract.* 36(3): 105-113.
- Nyland T.G., Mattoon J.S., Herrgesell E.J. and Wisner E.R. 2002. Liver. In: *Small Animal Diagnostic Ultrasound*. 2<sup>nd</sup> ed. T.G . Nyland and J.S. Mattoon (eds.) Philadelphia: W.B. Saunders Company. 93-127.