

3-1-2001

Ultrasound Diagnosis

Phiwipha Kamonrat

Follow this and additional works at: <https://digital.car.chula.ac.th/tjvm>



Part of the [Veterinary Medicine Commons](#)

Recommended Citation

Kamonrat, Phiwipha (2001) "Ultrasound Diagnosis," *The Thai Journal of Veterinary Medicine*: Vol. 31: Iss. 1, Article 7.

DOI: <https://doi.org/10.56808/2985-1130.1845>

Available at: <https://digital.car.chula.ac.th/tjvm/vol31/iss1/7>

This Other is brought to you for free and open access by the Chulalongkorn Journal Online (CUJO) at Chula Digital Collections. It has been accepted for inclusion in The Thai Journal of Veterinary Medicine by an authorized editor of Chula Digital Collections. For more information, please contact ChulaDC@car.chula.ac.th.

ULTRASOUND DIAGNOSIS

Phiwipha Kamonrat*

History

An eight-year-old, female, Great Dane German Shepherd dog was referred to the Chulalongkorn University, Small Animal, Veterinary Teaching Hospital for the treatment of a large, chronic, infected wound in the right inguinal area. Three weeks previously, the dog was injured in this area by a large piece of wood, opening a wound that was surgically closed by a veterinarian. Ten days later, the wound had become infected discharging a large amount of bloody purulent exudate. Small pieces of wood were removed from this wound before reclosure by another veterinarian but on the following day more pus and fresh blood was evident. The dog was depressed and had lost its appetite.

On physical examination, the dog had pale mucous membranes and some fever. The wound was

open and stained with pus and blood. The caudal abdomen was moderately tensed on palpation. Abnormal clinical parameters, included elevated serum alkaline phosphatase (461 units), mild leukocytosis (1.77×10^4 white blood cells/ μl , 85% neutrophils, 4% band cells, 2% eosinophils, 8% lymphocytes, 1% monocytes) and anemia (3.12×10^6 red blood cells/ μl , 9.0 g/dl hemoglobin, 24.2% hematocrit) with a blood morphology showing anisocytosis. Plain radiographs of the abdomen revealed marked constipation, with many pieces of ingested bone impacted in the distal colon. Abdominal visceral silhouettes were poorly visualized in the midventral abdomen. An abdominal ultrasonography was performed to obtain specific information.

*Department of Surgery, Faculty of Veterinary Science, Chulalongkorn University, Bangkok 10330, Thailand

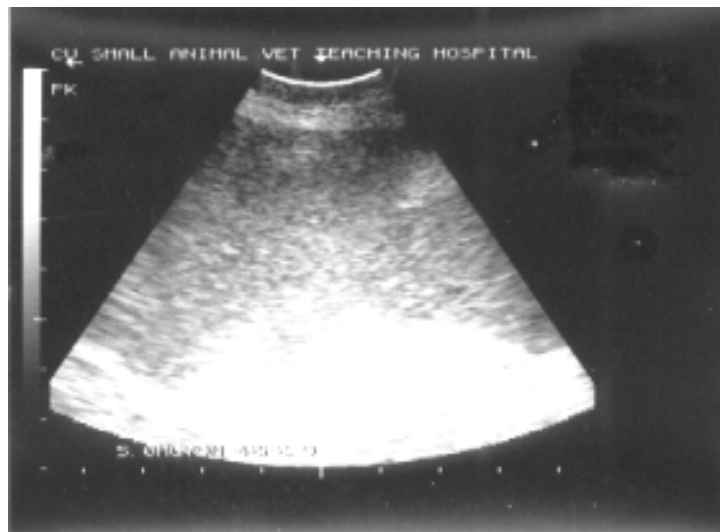


Figure 1 An ultrasonographic image of the caudal abdominal cavity in an eight-year-old, female dog, in lateral recumbency. A moderate amount of echogenic peritoneal fluid, with swirling of the echo observed in real time, was present between the bowel loop. Horizontal and vertical markings indicate centimeters.

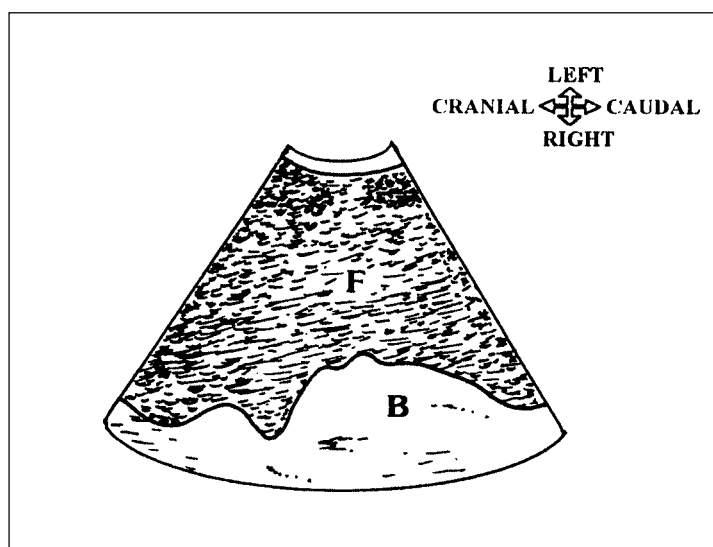


Figure 2 Schematics of the relative position of the structures scanned in figure 1. **F**-echogenic peritoneal fluid; **B**-bowel loop.

Ultrasonographic Findings

An ultrasonographic examination of the caudal abdomen was performed using an electronic, sector, real-time scanner of 5 MHz frequency. A moderate quantity of mildly echogenic fluid with multiple echoes, showing a swirling movement, was seen in the abdominal cavity (Fig.1 and 2). The small bowel with a clear serosal surface was floating within this fluid. The spleen and other intra-abdominal organs appeared more echoic than normal. An ultrasound-guided abdominocentesis was performed.

Diagnosis

Ultrasonographic diagnosis — Cellular ascites / peritonitis.

Comments

Ultrasonography appears to be a more sensitive imaging technique than survey radiography for the diagnosis of free peritoneal fluid (Henley et al., 1989). Dorsal recumbency and sternal recumbency, with the head up and the body elevated 45°, are the positions of choice to detect small amounts of free abdominal fluid. Areas which are easily viewed for small quantities of peritoneal fluid, are the apex of the urinary bladder, between the liver lobes, between the liver and the diaphragm, between the liver and the stomach, and between the spleen and the body wall (Mattoon and Nyland, 1995). Small amounts of fluid may also be detected, as focal areas, surrounding the organ of inflammation. Larger quantities of peritoneal fluid

can be easily detected by ultrasound. Intra-abdominal organs including vascular structures are clearly seen, since they are separated by large anechoic spaces of free fluid. The appearance of anechoic peritoneal fluid indicates a transudate or a modified transudate. Intra-abdominal haemorrhage, peritonitis and peritoneal fluid, secondary to carcinomatosis, usually appears as echogenic fluid with multiple echoes from cells, fibrin or other debris, that often show a swirling movement in real time. Ultrasound of the abdominal organs should be used to determine the potential origin of the fluid.

A definitive diagnosis of the presence of peritoneal fluid and the cause of the fluid requires fluid aspiration for analysis. Examination of pus from the peritoneal fluid, confirmed the presence of *Escherichia coli*.

References

- Henley, R.K., Hager, D.A., and Ackerman, N. 1989. A comparison of two-dimensional ultrasonography and radiography for the detection of small amounts of free peritoneal fluid in the dog. *Vet. Radiol.* 30(3): 121-124.
- Mattoon, J.S. and Nyland, T.G. 1995. Ultrasonography of the general abdomen. In: *Veterinary Diagnostic Ultrasound*. T.G. Nyland and J.S. Mattoon (eds.). Philadelphia : W.B. Saunders Company. 43-51.