

# The Thai Journal of Veterinary Medicine

---

Volume 30  
Issue 2 June, 2000

Article 7

---

6-1-2000

## What is Your Diagnosis?

Pranee Tuntivanich

Follow this and additional works at: <https://digital.car.chula.ac.th/tjvm>



Part of the [Veterinary Medicine Commons](#)

---

### Recommended Citation

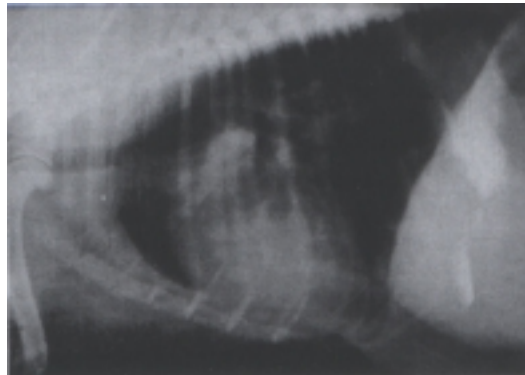
Tuntivanich, Pranee (2000) "What is Your Diagnosis?," *The Thai Journal of Veterinary Medicine*: Vol. 30: Iss. 2, Article 7.

Available at: <https://digital.car.chula.ac.th/tjvm/vol30/iss2/7>

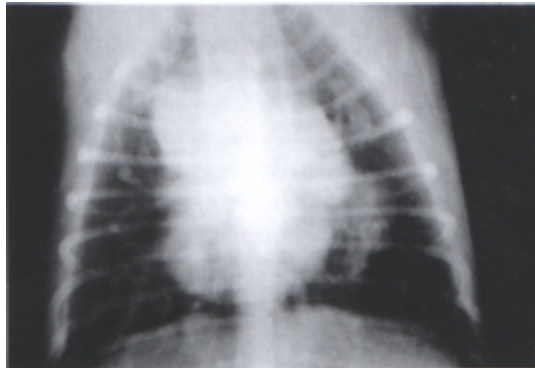
This Other is brought to you for free and open access by the Chulalongkorn Journal Online (CUJO) at Chula Digital Collections. It has been accepted for inclusion in The Thai Journal of Veterinary Medicine by an authorized editor of Chula Digital Collections. For more information, please contact [ChulaDC@car.chula.ac.th](mailto:ChulaDC@car.chula.ac.th).

## WHAT IS YOUR DIAGNOSIS

Pranee Tuntivanich\*



**Figure 1.** Lateral position of the chest of a dog



**Figure 2.** Vento-dorsal position of the chest of the same dog.

### History :

A seven year old female, mixed breed dog was presented suffering from dry coughing over a period of months. Examination revealed severe panting and three masses in the last third of the mammary gland were palpated. Radiographs of the thorax were taken in both the lateral and the ventro-dorsal positions.

Give your diagnosis and turn to the next page.

---

\* Department of Surgery, Faculty of Veterinary Science, Chulalongkorn University

**Radiographic Diagnosis :**

Heartworm disease.

Metastatic tumor in the lung.

**Radiographic Findings and Comments :**

The lateral and ventrodorsal views of the thorax revealed multiple pulmonary nodules and interstitial infiltrate in the lung area indicating a metastatic lesion. There was an ill-defined region of increased opacity around the tracheal bifurcation as result of tracheobronchial lymphadenopathy which can be difficult to identify. The trachea was pushed dorsally due to enlargement of the tracheo-bronchial lymph node. There was enlargement of the auricles and the right pulmonary vessel indicating heart worm disease.