

4-1-1972

## Experiencein gynecological laparoscopy at Chulalongkorn Hospital

Anek Aribarg

Wongkulpat Snidvongs

Follow this and additional works at: <https://digital.car.chula.ac.th/clmjjournal>



Part of the [Medicine and Health Sciences Commons](#)

---

### Recommended Citation

Aribarg, Anek and Snidvongs, Wongkulpat (1972) "Experiencein gynecological laparoscopy at Chulalongkorn Hospital," *Chulalongkorn Medical Journal*: Vol. 17: Iss. 4, Article 6.

Available at: <https://digital.car.chula.ac.th/clmjjournal/vol17/iss4/6>

This Article is brought to you for free and open access by the Chulalongkorn Journal Online (CUJO) at Chula Digital Collections. It has been accepted for inclusion in Chulalongkorn Medical Journal by an authorized editor of Chula Digital Collections. For more information, please contact [ChulaDC@car.chula.ac.th](mailto:ChulaDC@car.chula.ac.th).

# EXPERIENCE IN GYNECOLOGICAL LAPAROSCOPY AT CHULALONGKORN HOSPITAL

Anek Aribarg, M.B.B.S. (Lond.), M.R.C.O.G., D.C.H.\*

Wongkulpat Snidvongs, M.B.B.S. (Lond.), M.R.C.O.G.\*

## Introduction

Recently there is considerable interest of gynecological laparoscopy, in Thailand. Value of this procedure has been universally accepted for some years<sup>(5,13,14)</sup> However, it also has some problems. This communication describes experience of diagnostic and operative laparoscopy, at Chulalongkorn Hospital, between May 1970 to February 1973.

## Instruments

Instruments consisted of an 11 mm Storz fibre optic laparoscope, with an operating channel and forward-oblique Hopkin's telescope, attached to a cold light fountain. Semm pneumoperitoneum apparatus was used for carbon dioxide insufflation. Some intraperitoneal findings were photographed with a Robot camera.

## Anesthesia and Analgesia

Epidural analgesia was given to the majority of patients. General anesthesia with endotracheal intubation was only used in the patients who were nervous or when the epidural block technique failed. Some patients had local infiltration of 1 per cent xylocaine solution. with previous sedation. (See Table I).

**Table I:** Methods of Anesthesia and Analgesia.

<i>Methods</i>	<i>No. of Cases</i>
Epidural Analgesia	131
General Anesthesia	10
Local Anesthesia	14
Total	155

## Procedure

Majority of the patients were admitted into the hospital one day before the laparoscopic procedure. Pre-operative preparation was the same as for a major gynecological operation. Morphine  $\frac{1}{6}$  gr. and Atropine  $\frac{1}{100}$  gr. were given intramuscularly. The bladder was emptied. The patients were placed in supine horizontal position. The uterus could be manipulated either manually, or by the use of a small Hegar dilator, or a Spackman's intrauterine cannula.

When the anesthetic or analgesic procedure was complete and became effective, the Verres needle was inserted into the peritoneal cavity, just below the umbilicus, in the midline, to insufflate carbon dioxide. In some of the earlier cases, air was given. With Semm

\* Department of Obstetric and Gynaecology Chulalongkorn Hospital Medical School, Bangkok.

pneumoperitoneum apparatus, the flow of carbon dioxide was controlled at the rate of 1 litre per min. and the total volume of 2.5 to 3.5 litres were used. The intraperitoneal pressure was monitored and kept around 20 mm. of Hg.

The technique of laparoscopy was similar to that described by Steptoe<sup>(14)</sup>. For visualization of the pelvic organs, the operative table was tilted at 20 degree Trendelenburg position.

Electrocoagulation sterilization was performed by two different techniques, either by introducing a flexible electrocoagulation forceps into the peritoneal cavity, through the operating channel in the laparoscope; or by inserting a rigid electrocoagulation forceps through an extra puncture hole, midway between the umbilicus and the symphysis pubis.

Electrocoagulation was performed at two adjacent points, on each fallopian tube, near to the cornu of uterus, as described by Jordan<sup>(8)</sup>. The tubes were not divided.

On completion of the procedure, the gas was removed and the incision was closed with few subcuticular catgut sutures. The patient was discharged on the following day. The operative time lasted 15 to 45 minutes.

### **Results**

Between May 1970 to February 1973, laparoscopy was performed on 155 patients, by the authors, 93 for diagnosis and 62 for tubal sterilization. The age of the patients was ranged from 19 to 50 years. The indications for diagnostic laparoscopy are summarised in Table II and the findings are listed in Table III.

**Table II** : Indications for Laparoscopy

<i>Diagnostic Procedure</i>	
<i>Indications</i>	<i>No. of Patients</i>
Pelvic Pain	26
Pelvic Masses	21
Suspected Ectopic pregnancy	15
Amenorrhoea (Primary & Secondary)	10
Infertility	12
Displacement of I.U.C.D. (Intrauterine contraceptive device)	3
Virilism	3
Pelvic Malignancy Assessment	3
Total	93

**Table III :** Laparoscopic findings.

<i>Findings</i>	<i>No. of patients</i>
Ectopic Pregnancy	11
Ovarian Tumour	9
Myoma Uteri	7
Pelvic Inflammatory Diseases	14
Anomaly of genital tract	7
Endometriosis	4
Hydrosalpinx	3
Perforation of Uterus	6
Rupture of ovarian follicle	4
Carcinomatosis	3
Stein Leventhal Syndrome	2
Adrenogenital Syndrome	1
Abdominal Pregnancy	1
Pregnant Uterus	2
Normal findings	19
<b>Total</b>	<b>93</b>

Pelvic pain of uncertain etiology and ill defined pelvic masses were the main indications for diagnostic laparoscopy in this series. Normal pelvic findings were found in 21 patients, included two cases of uterine pregnancy. There were six cases of perforated uterus. Three of these were caused by the Lippes loop. However in only one instant that the displaced contraceptive device could be visualised and removed by the laparoscopy. In the other two patients, the intestines and the blood clots completely concealed the displaced loops. Laparotomy had to be performed. Perforation of uterus occurred during dilatation and curettage was diagnosed twice. Hemorrhage was easily controlled by light cautery and the treatment was simply conservative.

There were few complications. Parietal emphysema occurred in twelve patients. Few patients complained of mild shoulder tip pain either during the procedure or post operatively, particularly if air was used for pneumoperitoneum. In three cases, the pelvic organs were only partially visualized, because there were extensive pelvic adhesions, involved the intestines and the omentum. There was one case of wound infection which satisfactorily responded to antibiotic therapy. Occasionally local anasthesia and epidural block technique failed and were inadequate for the operation. Additional sedative or anesthetic gas had to be administered. In one instant, the local infiltration of xylocaine solution provided

inadequate analgesia and the operation had to be abandoned. There was no mortality.

Tubal sterilization by laparoscopic technique was performed on 62 patients and the details were briefly summarised in Table IV. Majority of cases were performed during puerperium, two to

seven days after delivery. In one case of puerperial tubal sterilization, the enlarged uterus was perforated by the laparoscopic trocha. Laparotomy was subsequently performed to repair the injury and the sterilization was carried out by the Pomeroy technique.

**Table IV :** Details of Tubal electrocoagulation.

<i>Types</i>	<i>No. of Cases.</i>
Postpartum	42
Interval	20
<i>Techniques</i>	<i>No. of Cases.</i>
"Single Puncture"	48
"Double Puncture"	14
Total	62

### **Discussion**

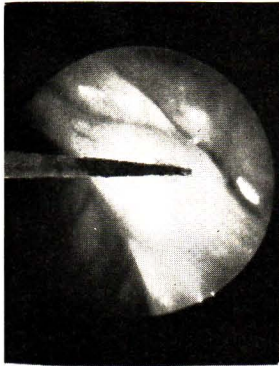
Laparoscopy is a very effective technique for gynecological diagnosis and tubal sterilization. It is preferred to culdoscopy<sup>(4)</sup>. Ideally laparoscopy should be carried out under general anesthesia with endotracheal intubation and controlled respiration<sup>(1)</sup>. However this procedure requires a skill anesthetist. At Chulalongkorn Hospital, epidural block is used for the majority of cases because it is convenient, safe and adequate<sup>(2)</sup>. Local Anesthesia is usually inadequate for operative laparoscopy. Additional pre-operative sedation is recommended in all cases.

Air, oxygen, carbon dioxide and nitrous oxide have all been used for

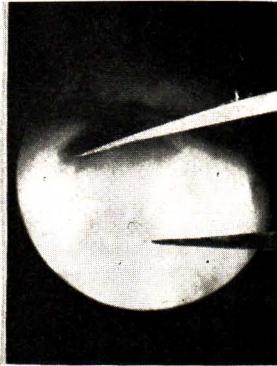
pneumoperitoneum. The internists have been using air or oxygen for pneumoperitoneum for some time<sup>(12)</sup>. Air is inabsorbable and can cause fatal air embolism<sup>(7)</sup>. Shoulder tip pain is frequently experienced with air. Oxygen is contraindicated, if using electrocoagulation. Nitrous oxide is thought to be more suitable<sup>(6)</sup>. However, it is not universally accepted<sup>(11)</sup>. Carbon dioxide is extensively used for pneumoperitoneum. It is absorbed from the peritoneum during the operation and causes hypercarbia<sup>(3)</sup>. Using halothane anesthesia in the presence of elevated pCO<sub>2</sub> level can produce cardiac arrhythmias<sup>(11)</sup>. Difficulties and serious complications may occur during pneumoperitoneum procedure. With the use of Semm

**PHOTOGRAPHS OF INTRAPERITONEAL FINDINGS**

ECTOPIC  
PREGNANCY

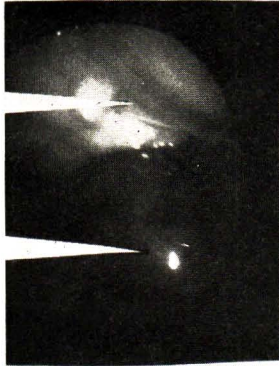

PERFORATION

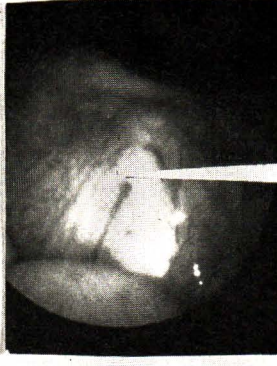


UTERUS

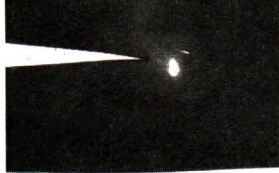OMENTUM



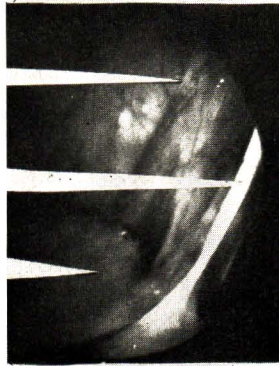MYOMA UTERI



OVARIAN CYST

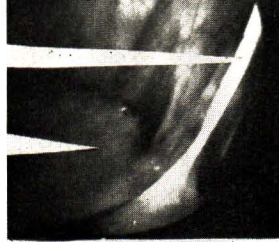


BLADDER

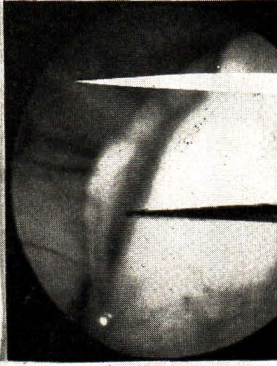


BLADDER

PELVIC ADHESIONS

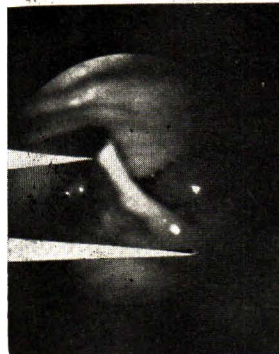

HYDROSALPINX



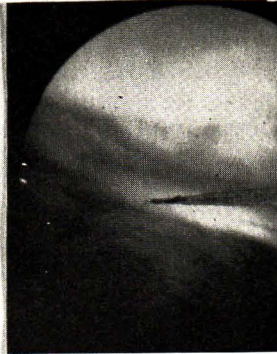UTERUS

ELECTRO  
COAGULATION  
FORCEPS



RUDIMENTARY  
UTERUS

FALLOPIAN TUBE



apparatus, carbon dioxide insufflation is easier and safer.

Our series of laparoscopic sterilization is small compared with others<sup>(8, 15)</sup>. It is premature to assess the results. We did a few hystero-graphy on our patients, three months post-operatively. This method of assessment, however, is expensive, impracticable and inconclusive. The procedure could by itself produce fistula<sup>(10)</sup>. It is debatable whether division of the tubes is necessary or not<sup>(9)</sup>. However, the electrocoagulation procedure must be thoroughly performed. Laparoscopic sterilization by the "single puncture" technique is slightly more difficult to master than the "double puncture" method. Using an intrauterine cannula to manipulate the uterus is essential for the "single puncture" technique. In our experience, puerperal sterilization by the laparoscope has no advantage over the conventional tubal ligation by the Pomeroy technique. The patients are usually kept in hospital one day after the operation. Wheeler has shown that laparoscopic sterilization can be carried out as an Out-patient procedure<sup>(16)</sup>.

### Conclusion

Between May 1970 to February 1973, diagnostic and operative laparoscopies were performed on 155 patients by the authors. With our short experience, we have come to the following conclusions:-

1. Laparoscopy has considerable value in gynecological diagnosis and tubal sterilization. However it also has some problems.

2. Diagnosis of uterine perforation due to dilatation and curettage can be definitely made by laparoscopy.

3. Removal of a displaced intrauterine contraceptive device can be conveniently performed by the laparoscope, but sometimes there are difficulties.

4. Laparoscopic tubal sterilization, performing during puerperium has no particular advantage over the conventional tubal ligation by the Pomeroy technique.

### Acknowledgements

We are most grateful to Professor M.L. Kaset Snidvongs, the former Dean of the Chulalongkorn Medical School; Professor Charanpat Israngkun, the Head of the department of Obstetrics and Gynecology; and Assistant Professor Sommai Wilairat, the Head of the Division of Gastroenterology, Department of Medicine, for their help and encouragement.

### References

1. Alexander, G.D., Noe F.E. and Brown, E.M., Anesthesia for Pelvic Laparoscopy; *Anesth. Analg.* (Cleveland) 46: 14: 1969.
2. Aribarg, A., Epidural Analgesia for Laparoscopy; *J. Obstet. Gynae. Brit. Cwlt.*: In Press.
3. Baratz, R.A. and Karis, J.H., Blood Gas studies during Laparoscopy under General Anesthesia 2; *Anesth.* 30: 463; 1969.
4. Cohen, M.R., Culdoscopy Vs Peritoneoscopy; *Obstet. Gynec.* 31: 310; 1968.
5. Cohen, M.R., Laparoscopy, Culdoscopy and Gynecography. Technique and Atlas, Saunders, Philadelphia, 1970.
6. Corson, S.L. Bologness, R.J., Laparoscopic Nuances; *Fertil. Steril.* 22: 684; 1971.

7. Jernstrom. P., Air Embolism during Peritoneoscopy: *Amer. J. Clin. Path.* 21: 573; 1951.

8. Jordan, J.A., Logan Edwards R., Person, J., Maskerg P.J.K., Laparoscopic Sterilization and Follow - Up Hysterosalpingogram; *J. Obstet. Gynae. Brit. Cwlth.* 78: 460; 1971.

9. Liston W.A., Downie, J., Bradford. W., and Kerr, M.G. Female Sterilization by Tubal Electrocoagulation under Laparoscopic Control; *Lancet*, 1: 382; 1970.

10. Peterson, E.P., Behrman S.J., Laparoscopy of the Infertile Patients; *Amer. J. Obstet. Gynec.* 110: 24; 1971.

11. Peterson, E.P., Anesthesia for Laparoscopy; *Fertil. Steril.* 22: 695; 1971.

12. Ruddock, J.C., Peritoneoscopy : a critical Clinical Review; *Surg. Clin. N. Amer.* 37: 124; 19579.

13. Siegler, A., Trends in Laparoscopy; *Amer. J. Obstet. Gynec.* 109: 794; 1970.

14. Steptoe, P.C., Laparoscopy in Gynaecology, Livingston, London, 1967.

15. Steptoe, P.C., Recent Advances in Surgical Methods of Control of Fertility and Infertility; *Brit. Med. Bull.* 26; 60; 1970.

16. Wheelless, C.R., Outpatient Tubal Sterilization; *Obstet Gynec.*, 36: 208, 1970.

