

12-1-1993

What is your diagnosis

Pranee Tuntivanich

Follow this and additional works at: <https://digital.car.chula.ac.th/tjvm>



Part of the [Veterinary Medicine Commons](#)

Recommended Citation

Tuntivanich, Pranee (1993) "What is your diagnosis," *The Thai Journal of Veterinary Medicine*: Vol. 23: Iss. 4, Article 4.

DOI: <https://doi.org/10.56808/2985-1130.1626>

Available at: <https://digital.car.chula.ac.th/tjvm/vol23/iss4/4>

This Article is brought to you for free and open access by the Chulalongkorn Journal Online (CUJO) at Chula Digital Collections. It has been accepted for inclusion in The Thai Journal of Veterinary Medicine by an authorized editor of Chula Digital Collections. For more information, please contact ChulaDC@car.chula.ac.th.

What is your diagnosis

*Pranee Tuntivanich**

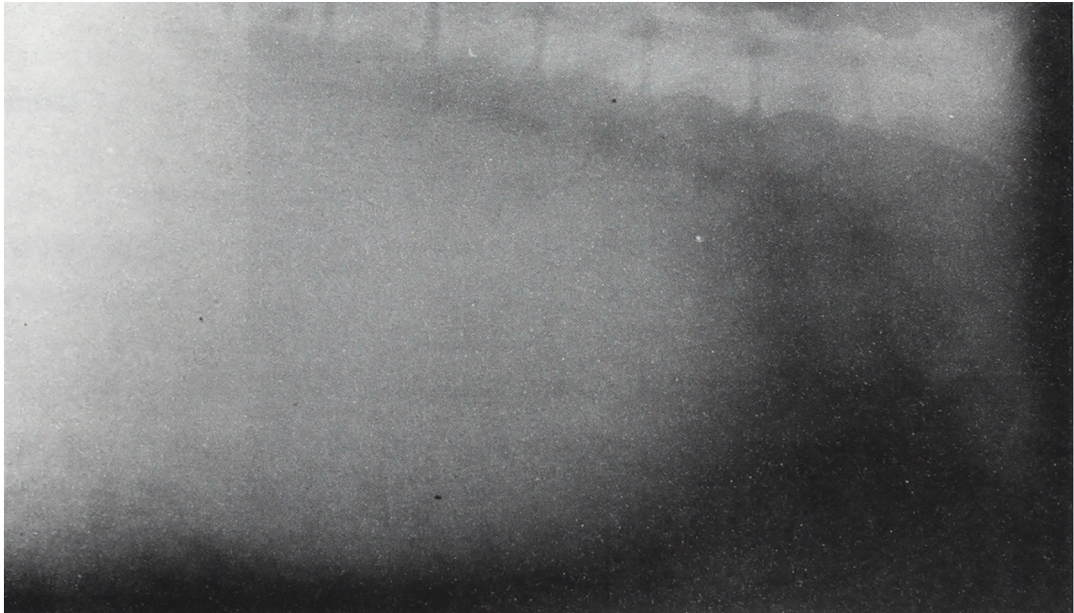


Figure 1. Lateral position of the abdomen of a 7 years old male Datchshund.

* Department of Surgery. Faculty of Veterinary Science, Chulalongkorn University, Bangkok 10330.

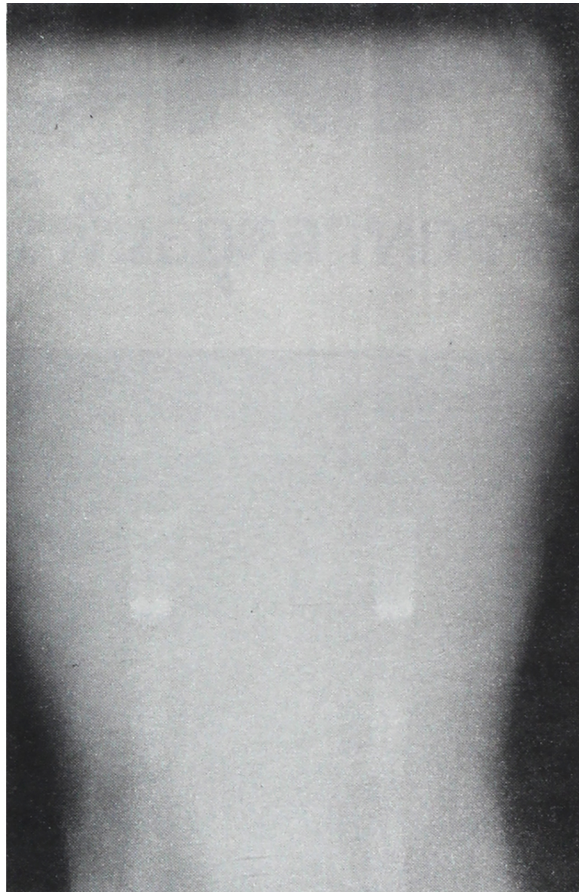


Figure 2. Ventro-dorsal position of an abdomen of the same dog.

History

A 7 years old male Datchschund had a history of distended abdomen and bloody stool. On palpation revealed pain at the lateral side of the penis.

Radiographs were taken on both lateral and ventrodorsal of the abdomen.

Give your diagnosis and turn to page 360.