

The Thai Journal of Veterinary Medicine

Volume 21
Issue 4 December, 1991

Article 3

12-1-1991

What is your diagnosis

Pranee Tuntivanich

Follow this and additional works at: <https://digital.car.chula.ac.th/tjvm>



Part of the [Veterinary Medicine Commons](#)

Recommended Citation

Tuntivanich, Pranee (1991) "What is your diagnosis," *The Thai Journal of Veterinary Medicine*: Vol. 21: Iss. 4, Article 3.

Available at: <https://digital.car.chula.ac.th/tjvm/vol21/iss4/3>

This Article is brought to you for free and open access by the Chulalongkorn Journal Online (CUJO) at Chula Digital Collections. It has been accepted for inclusion in The Thai Journal of Veterinary Medicine by an authorized editor of Chula Digital Collections. For more information, please contact ChulaDC@car.chula.ac.th.

What is your diagnosis

*Pranee Turtivanich **

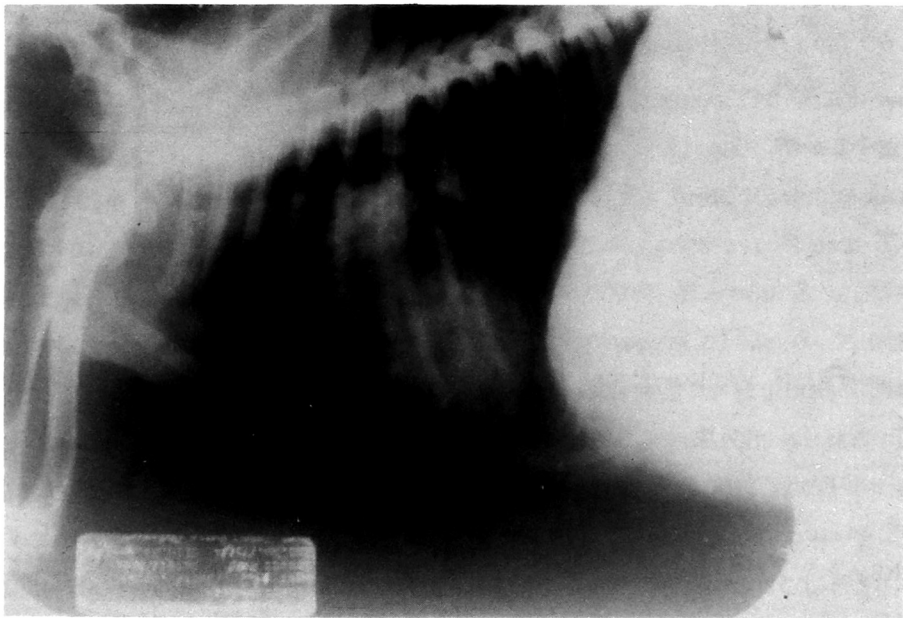


Fig. 1 Lateral view of the chest of a 2 years old dog

* Department of Surgery, Faculty of Veterinary Science, Chulalongkorn University, Bangkok 10330, Thailand.

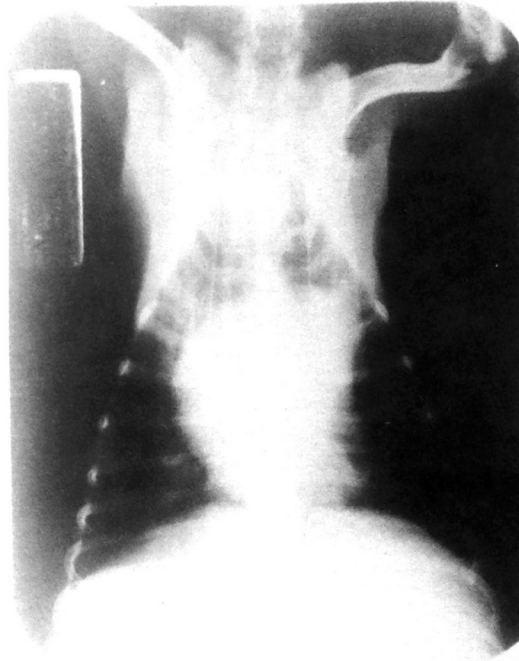


Fig. 2 Ventro-dorsal view of the chest of the same dog as in Fig. 1

History :

A two years old female mixed breed dog was presented with difficulty breathing and coughing for 2 months. Clinical examination revealed pale mucous membrane, weak and restlessness.

Radiographs of the chest were taken on lateral and ventro-dorsal views.

Give your diagnosis and turn to page 256