

The Thai Journal of Veterinary Medicine

Volume 15
Issue 4 December, 1985

Article 3

12-1-1985

What is your Diagnosis

Pranee Tuntivanich

Follow this and additional works at: <https://digital.car.chula.ac.th/tjvm>



Part of the [Veterinary Medicine Commons](#)

Recommended Citation

Tuntivanich, Pranee (1985) "What is your Diagnosis," *The Thai Journal of Veterinary Medicine*: Vol. 15: Iss. 4, Article 3.

DOI: <https://doi.org/10.56808/2985-1130.1420>

Available at: <https://digital.car.chula.ac.th/tjvm/vol15/iss4/3>

This Article is brought to you for free and open access by the Chulalongkorn Journal Online (CUJO) at Chula Digital Collections. It has been accepted for inclusion in The Thai Journal of Veterinary Medicine by an authorized editor of Chula Digital Collections. For more information, please contact ChulaDC@car.chula.ac.th.

What is your diagnosis

Pranee Tuntivanich D.V.M., M.S. (Rad.)

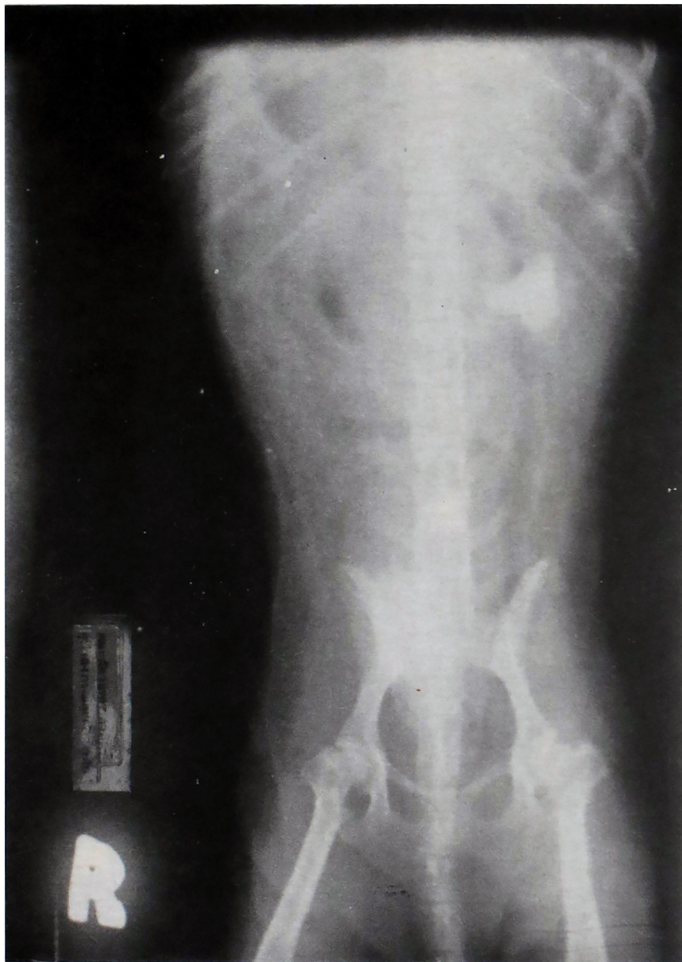


Fig. 1 Survey ventro-dorsal position of an abdomen of a 3 years old dog.

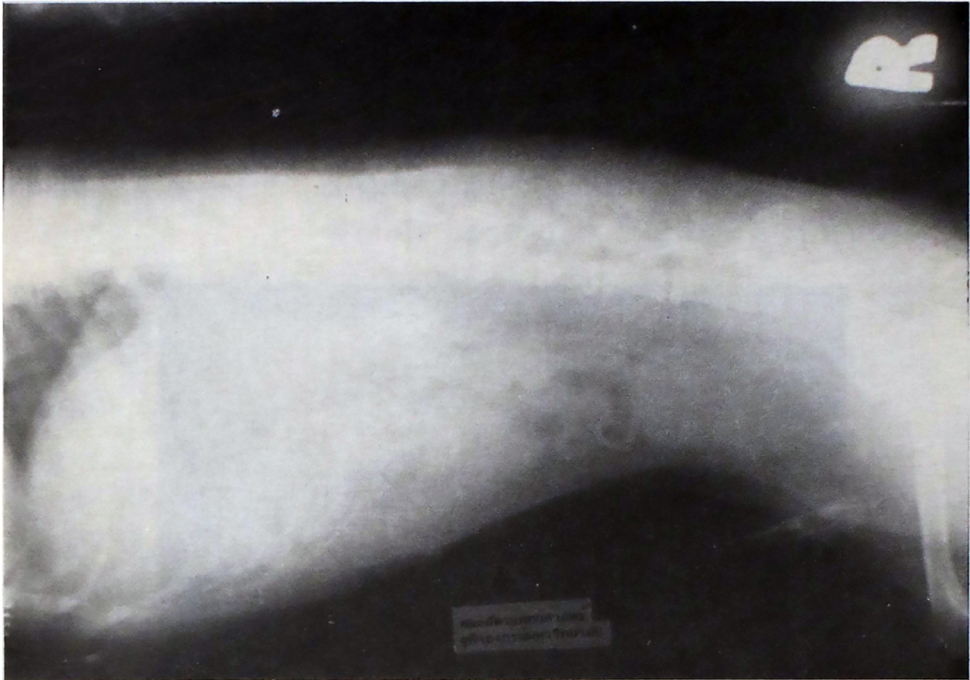


Fig. 2 Lateral position of the same dog.

History

A four years old male dog was suffered from abdominal pain, dripping urine and inappetite. The dog had been treated from private clinic 4 days prior to submit to Chulalongkorn small animal hospital. Urine culture revealed non-hemolytic *E. coli*.

Radiographs were taken on ventro-dorsal and lateral positions of an abdomen.

Give your diagnosis and turn to page 313