

6-1-1985

What is your Diagnosis

Pranee Tuntivanich

Follow this and additional works at: <https://digital.car.chula.ac.th/tjvm>



Part of the [Veterinary Medicine Commons](#)

Recommended Citation

Tuntivanich, Pranee (1985) "What is your Diagnosis," *The Thai Journal of Veterinary Medicine*: Vol. 15: Iss. 2, Article 3.

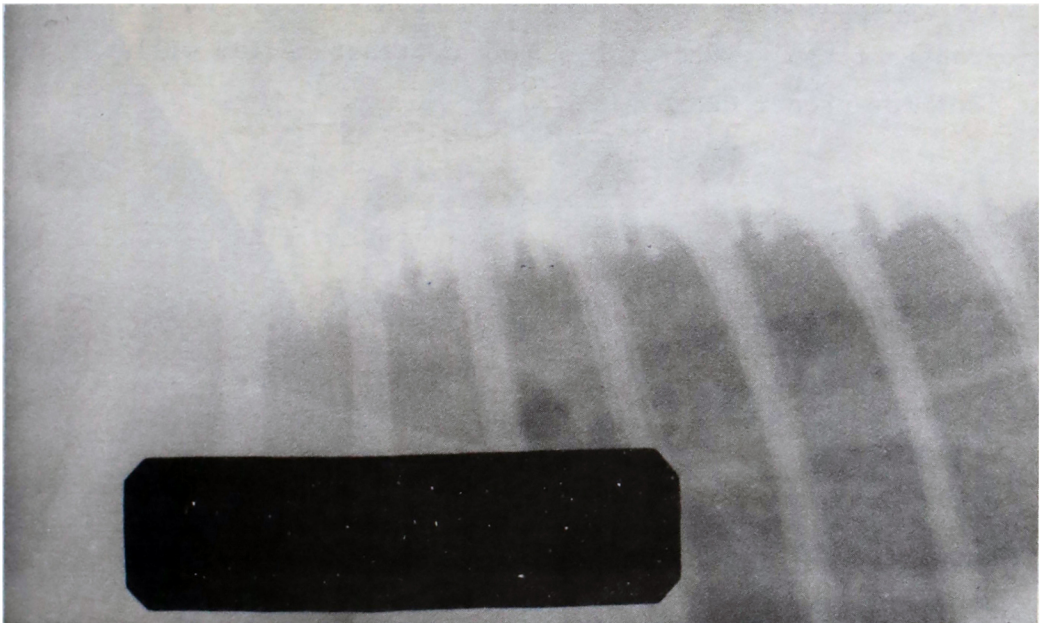
DOI: <https://doi.org/10.56808/2985-1130.1406>

Available at: <https://digital.car.chula.ac.th/tjvm/vol15/iss2/3>

This Article is brought to you for free and open access by the Chulalongkorn Journal Online (CUJO) at Chula Digital Collections. It has been accepted for inclusion in The Thai Journal of Veterinary Medicine by an authorized editor of Chula Digital Collections. For more information, please contact ChulaDC@car.chula.ac.th.

What is your diagnosis

Pranee Tuntivanich D.V.M., M.S.



Lateral view of thoracic vertebrae of a 6 years old cat.

History

A six years old male cat had been suffered from thoracic pain for one week before he was present to the hospital. There was no history of any trauma. On palpation of the spines, the cat was very sensitive along the area of the thoracic vertebrae. A radiograph was taken on lateral position.

Give your diagnosis and turn to page 134.

Radiographic diagnosis

Spondylosis of the ventral floor of T₃₋₁₀

Radiographic findings and comments

In contrary to dogs, spondylosis of the vertebrae is hardly seen in cats. Normally, spondylosis of the ventral floor of vertebrae will not cause any symptom besides spondylosis of the dorsal floor of the vertebrae. Back pain or paresis of hind limbs due to spondylosis is usually associated with spondylitis. However, special radiography of the vertebrae by using contrast medium will be the best tool for proper diagnosis.