

The Thai Journal of Veterinary Medicine

Volume 13
Issue 4 December, 1983

Article 2

12-1-1983

What is your Diagnosis

Pranee Tuntivanich

Follow this and additional works at: <https://digital.car.chula.ac.th/tjvm>



Part of the [Veterinary Medicine Commons](#)

Recommended Citation

Tuntivanich, Pranee (1983) "What is your Diagnosis," *The Thai Journal of Veterinary Medicine*: Vol. 13: Iss. 4, Article 2.

DOI: <https://doi.org/10.56808/2985-1130.1359>

Available at: <https://digital.car.chula.ac.th/tjvm/vol13/iss4/2>

This Article is brought to you for free and open access by the Chulalongkorn Journal Online (CUJO) at Chula Digital Collections. It has been accepted for inclusion in The Thai Journal of Veterinary Medicine by an authorized editor of Chula Digital Collections. For more information, please contact ChulaDC@car.chula.ac.th.

What is your diagnosis

*Pranee Tuntivanich D.V.M., M.S. (Rad)**

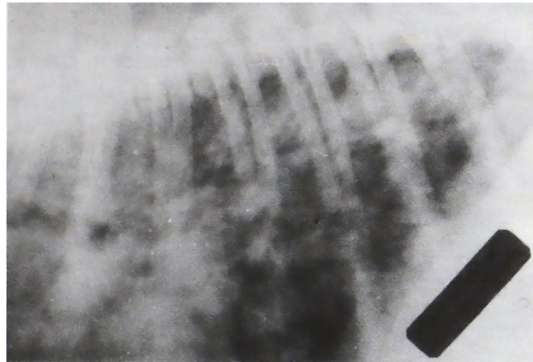


Fig. 1 Lateral position of the chest of a Boxer

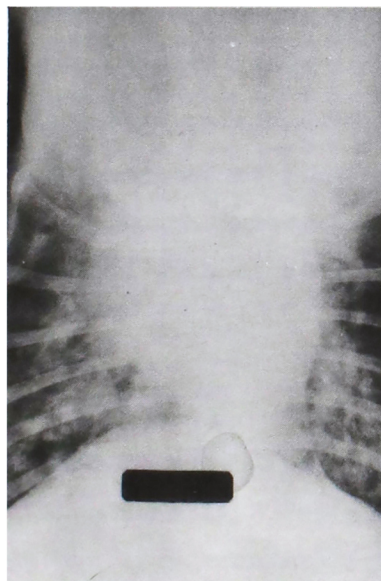


Fig. 2 Ventro-dorsal position of the chest of the same dog

* Department of surgery, Faculty of Veterinary Science, Chulalongkorn University, Bangkok 10500

History

A 2-years old female Boxer was suffered from moist cough for 2 months. She was still alert even though her appetite decreased. Blood test showed no incidence of microfilariasis.

Radiographs of the chest were taken on lateral and ventro-dorsal positions.

Give your diagnosis and turn to page 311