

The Thai Journal of Veterinary Medicine

Volume 6
Issue 4 December, 1976

Article 2

12-1-1976

What is your Diagnosis

P. Tuntivanich

Follow this and additional works at: <https://digital.car.chula.ac.th/tjvm>



Part of the [Veterinary Medicine Commons](#)

Recommended Citation

Tuntivanich, P. (1976) "What is your Diagnosis," *The Thai Journal of Veterinary Medicine*: Vol. 6: Iss. 4, Article 2.

Available at: <https://digital.car.chula.ac.th/tjvm/vol6/iss4/2>

This Article is brought to you for free and open access by the Chulalongkorn Journal Online (CUJO) at Chula Digital Collections. It has been accepted for inclusion in The Thai Journal of Veterinary Medicine by an authorized editor of Chula Digital Collections. For more information, please contact ChulaDC@car.chula.ac.th.

What is your diagnosis

* P. Tuntivanich D.V.M.,M.S.(Rad.)

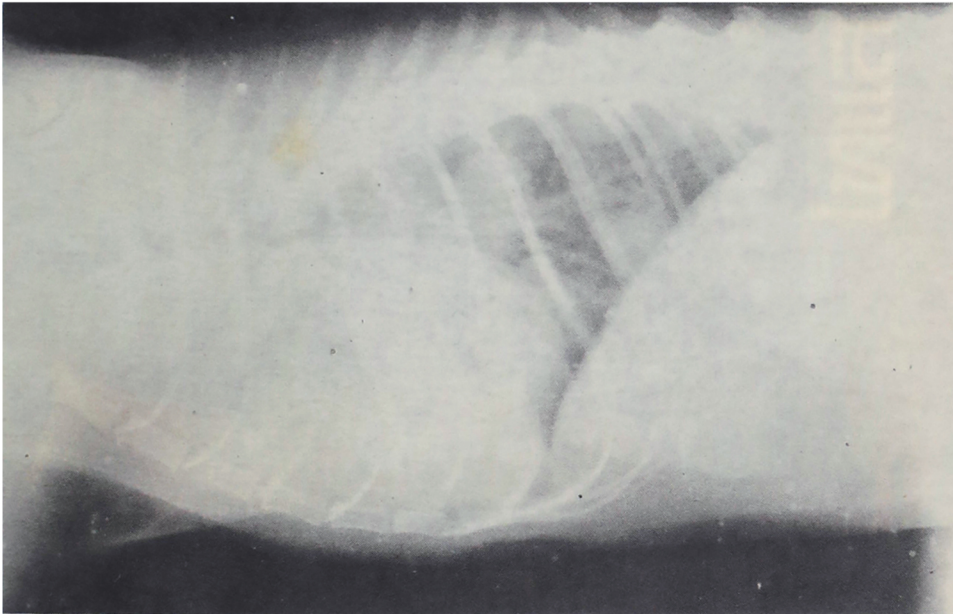


Fig. 1 Lateral view of the thorax

HISTORY

A one-year-old female cat was examined because of coughing and vomiting. A mass was present at the region of parotid lymphnode. A radiograph was taken at the thoracic part.

Give your diagnosis and turn to page. 216

*Department of Surgery, Faculty of Veterinary Science,
Chulalongkorn University.