

The Thai Journal of Veterinary Medicine

Volume 6
Issue 1 *March, 1976*

Article 2

3-1-1976

What is your Diagnosis

P. Tuntivanich

Follow this and additional works at: <https://digital.car.chula.ac.th/tjvm>



Part of the [Veterinary Medicine Commons](#)

Recommended Citation

Tuntivanich, P. (1976) "What is your Diagnosis," *The Thai Journal of Veterinary Medicine*: Vol. 6: Iss. 1, Article 2.

Available at: <https://digital.car.chula.ac.th/tjvm/vol6/iss1/2>

This Article is brought to you for free and open access by the Chulalongkorn Journal Online (CUJO) at Chula Digital Collections. It has been accepted for inclusion in The Thai Journal of Veterinary Medicine by an authorized editor of Chula Digital Collections. For more information, please contact ChulaDC@car.chula.ac.th.

What is your diagnosis

* P. Tuntivanich D.V.M., M.S.(in Rad)

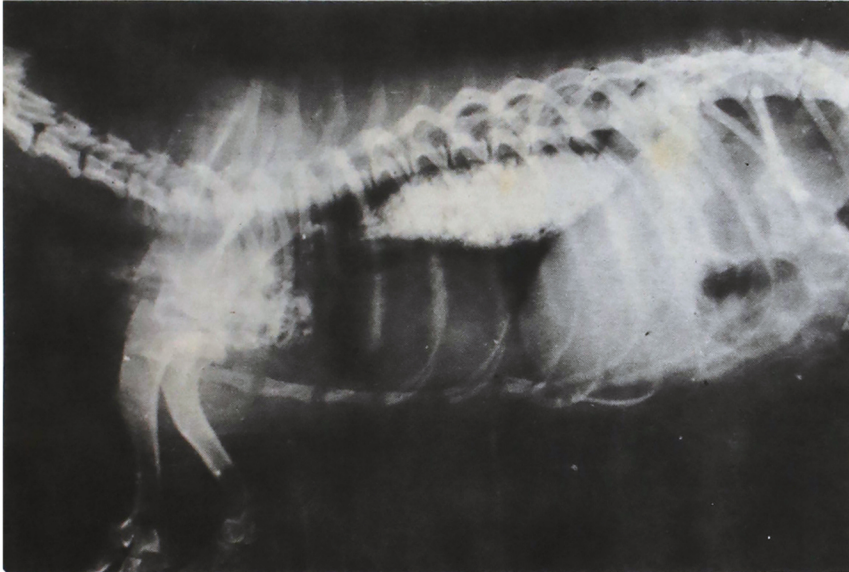


Fig. 1 Radiograph, lateral view, of the thorax

History A male Pekingese, 4 years old, suffered from persistent vomiting. Vomition occurred shortly after the food was eaten. The animal acted normally. A radiograph was taken right after the barium solution was given by mouth.

Give your diagnosis and turn to page 12

* Department of Veterinary Surgery, Faculty of Veterinary Science, Chulalongkorn University.